

## Diagnosing Broiler Leg Problems

These images were developed from a seminar presented at a meeting of the Georgia Poultry Nutrition Roundtable, November 1998, by Dr.'s George N. Rowland, III, and Hardy M. Edwards, Jr. Dr. Rowland is professor of Avian Medicine and Dr. Edwards is an Alumni Foundation Distinguished Professor of Poultry Science and Animal Nutrition at the University of Georgia.

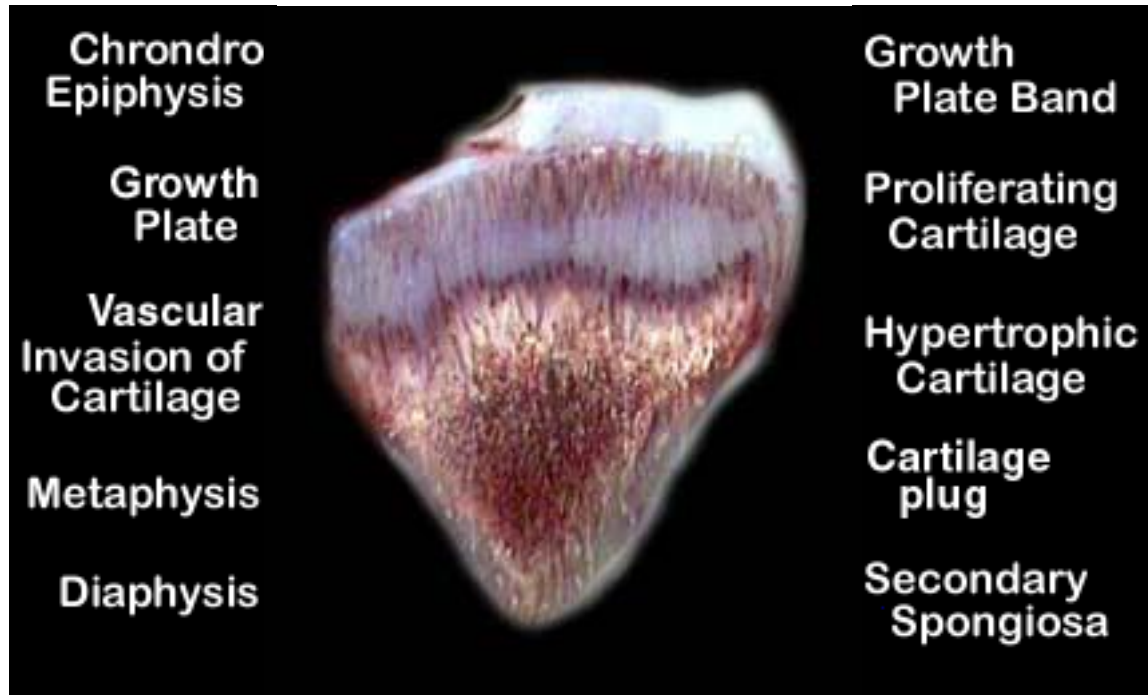
The images were prepared by Dr. Jan G. Hogle.

Please see our web site at <http://www.uga.edu/poultry/courses/legs> for more information.

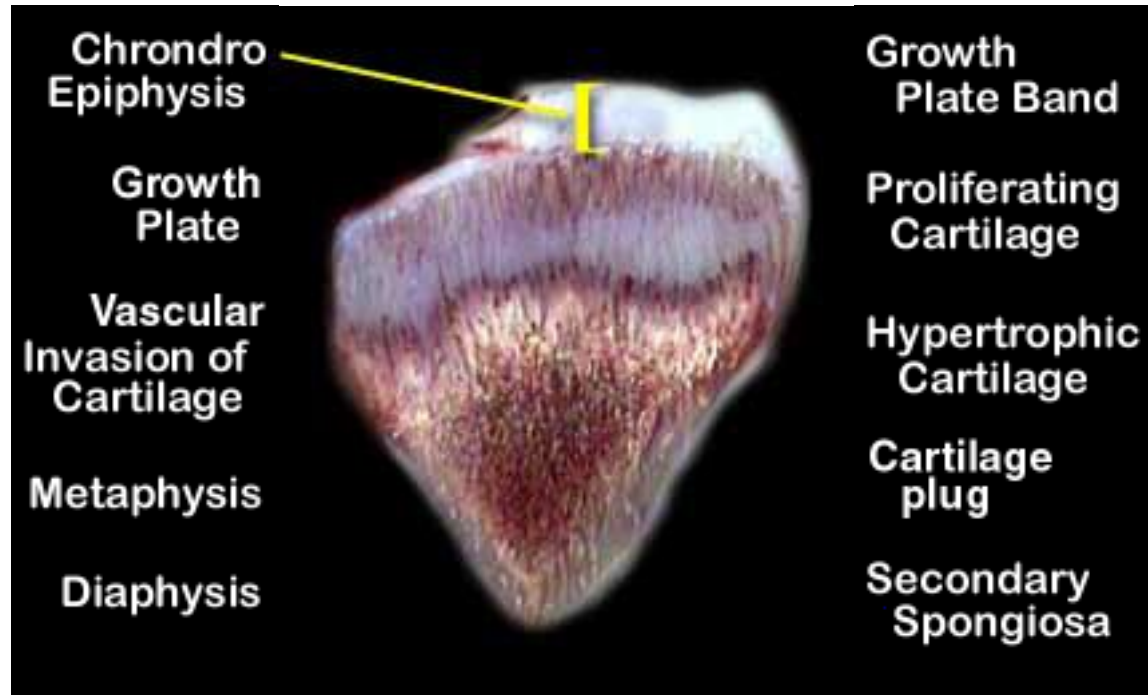
© Copyright 1999. The University of Georgia.

For Instructional Purposes Only.

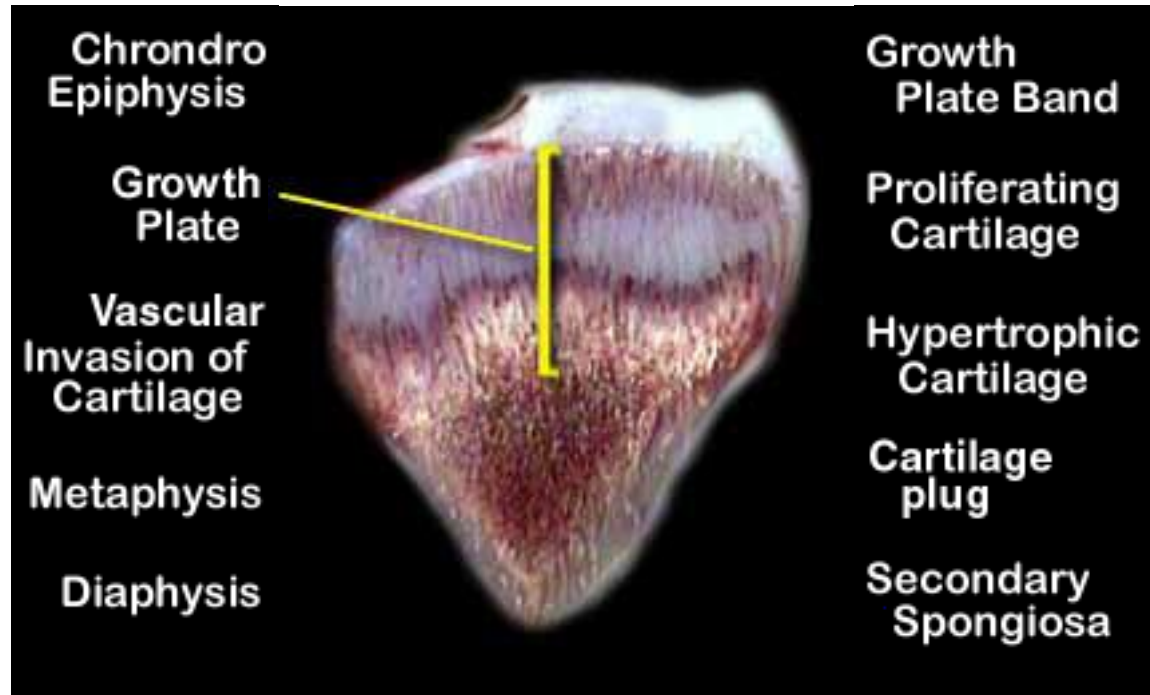
# Calcium/Vitamin D Rickets



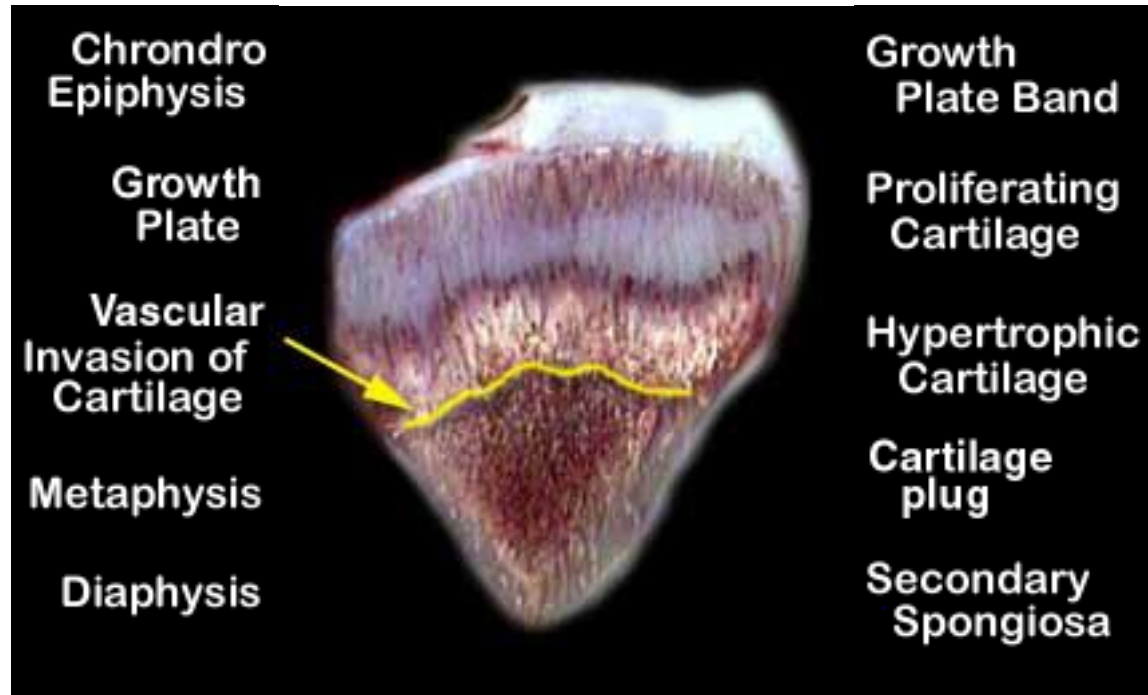
# Calcium/Vitamin D Rickets



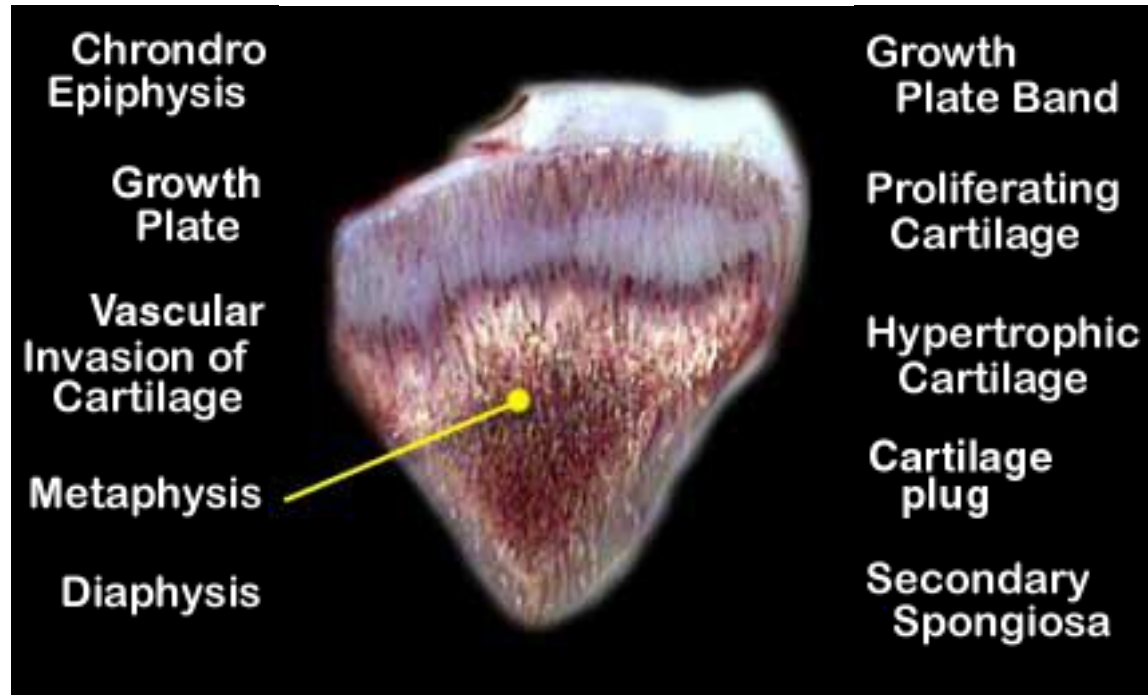
# Calcium/Vitamin D Rickets



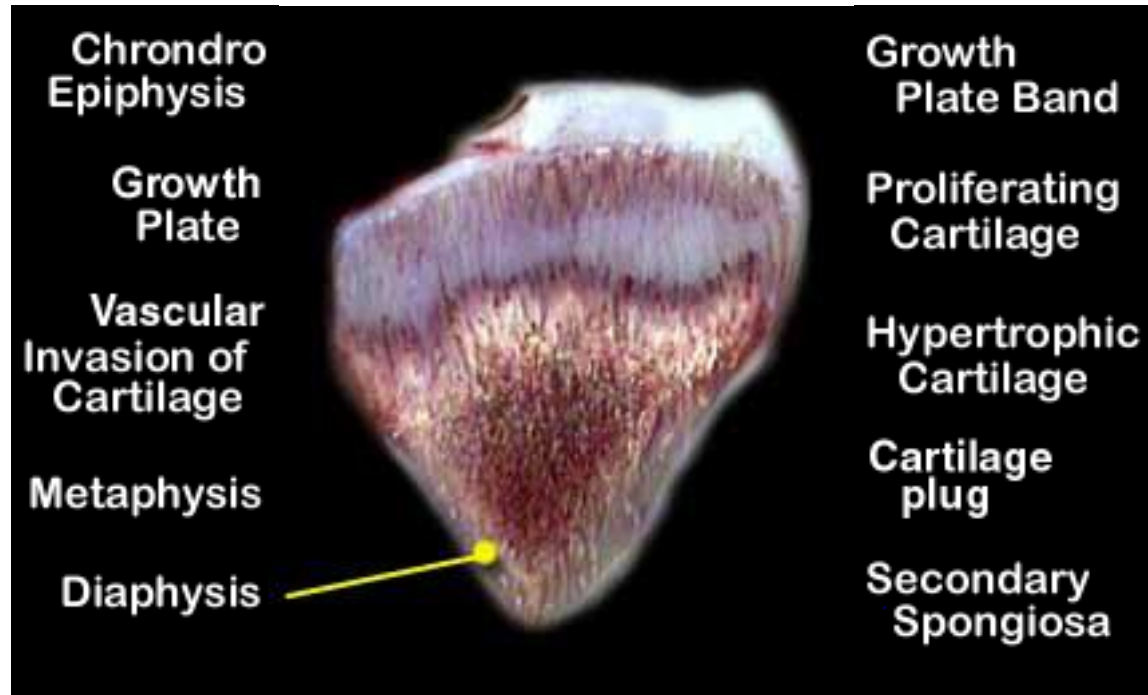
# Calcium/Vitamin D Rickets



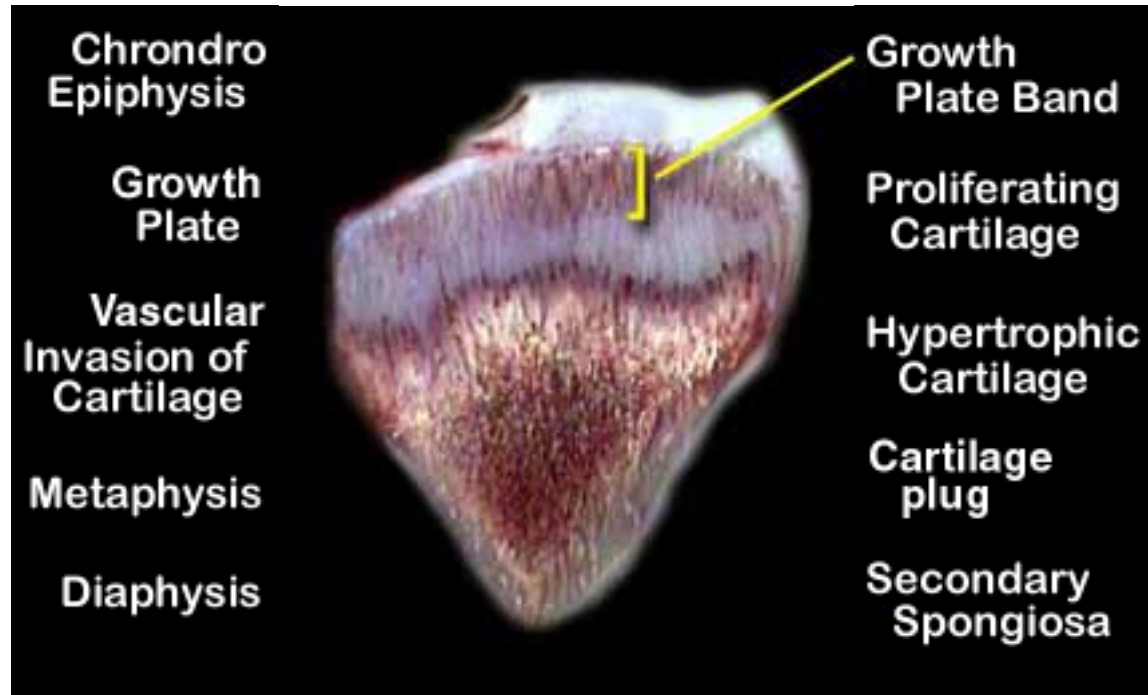
# Calcium/Vitamin D Rickets



# Calcium/Vitamin D Rickets

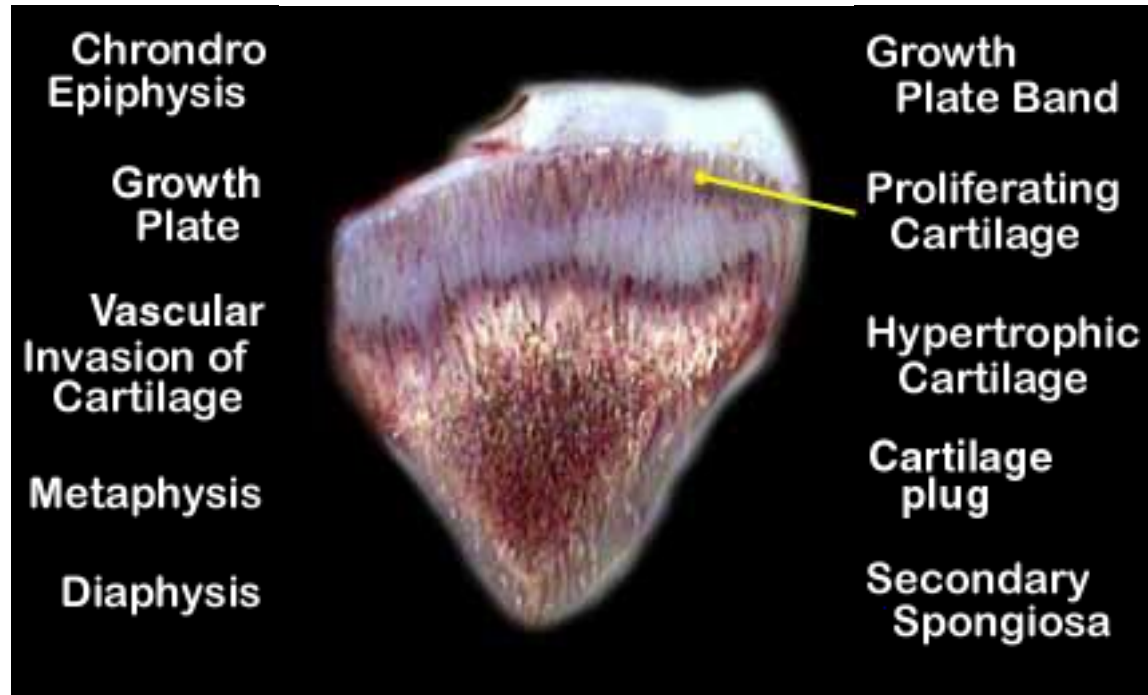


# Calcium/Vitamin D Rickets

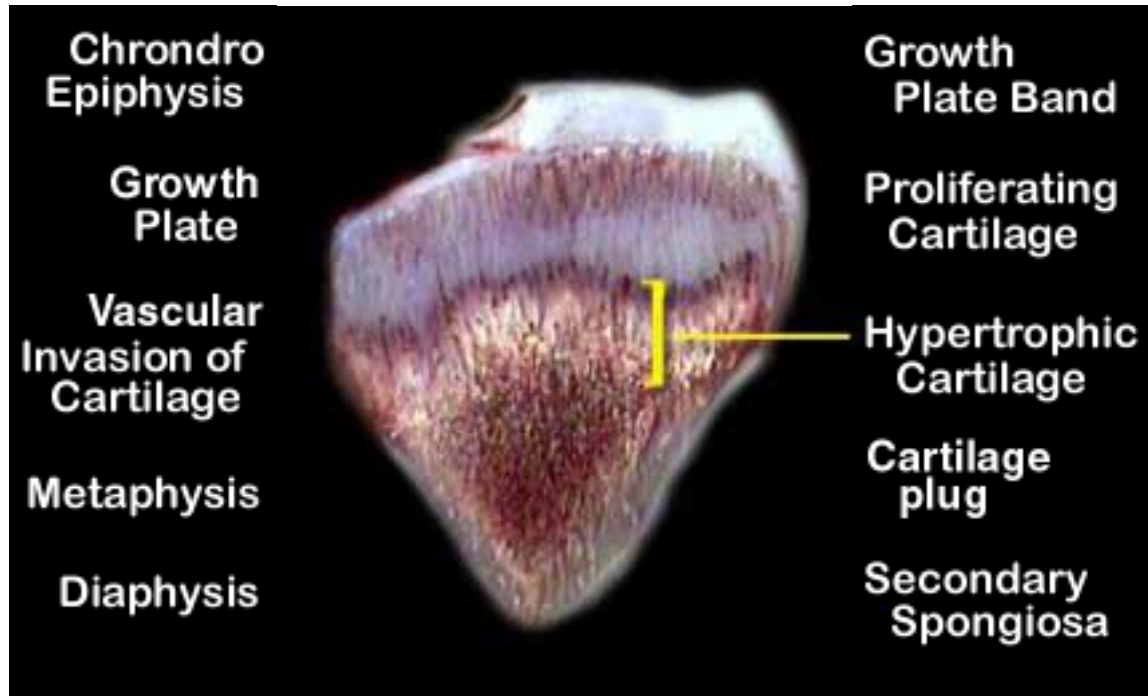




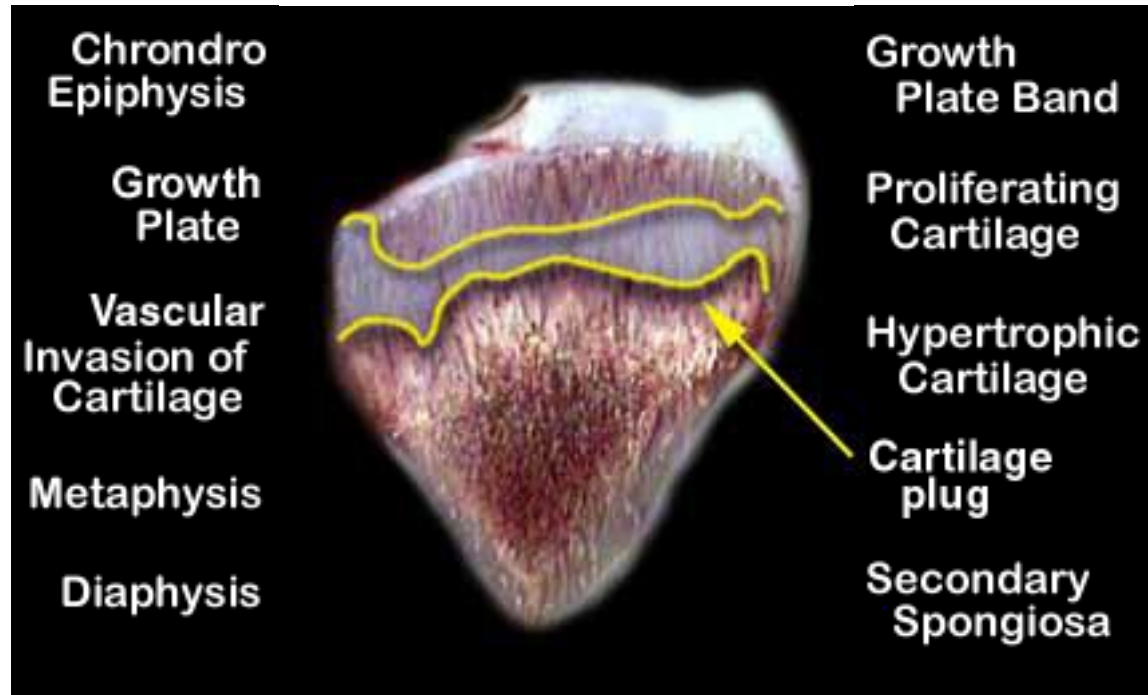
# Calcium/Vitamin D Rickets



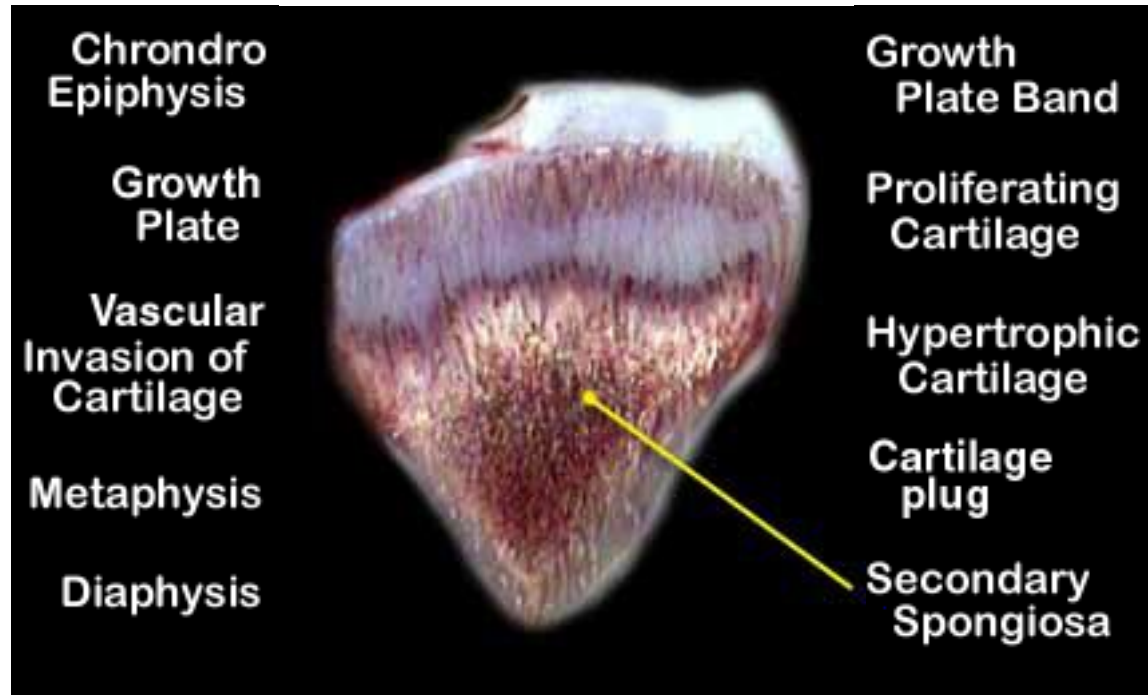
# Calcium/Vitamin D Rickets



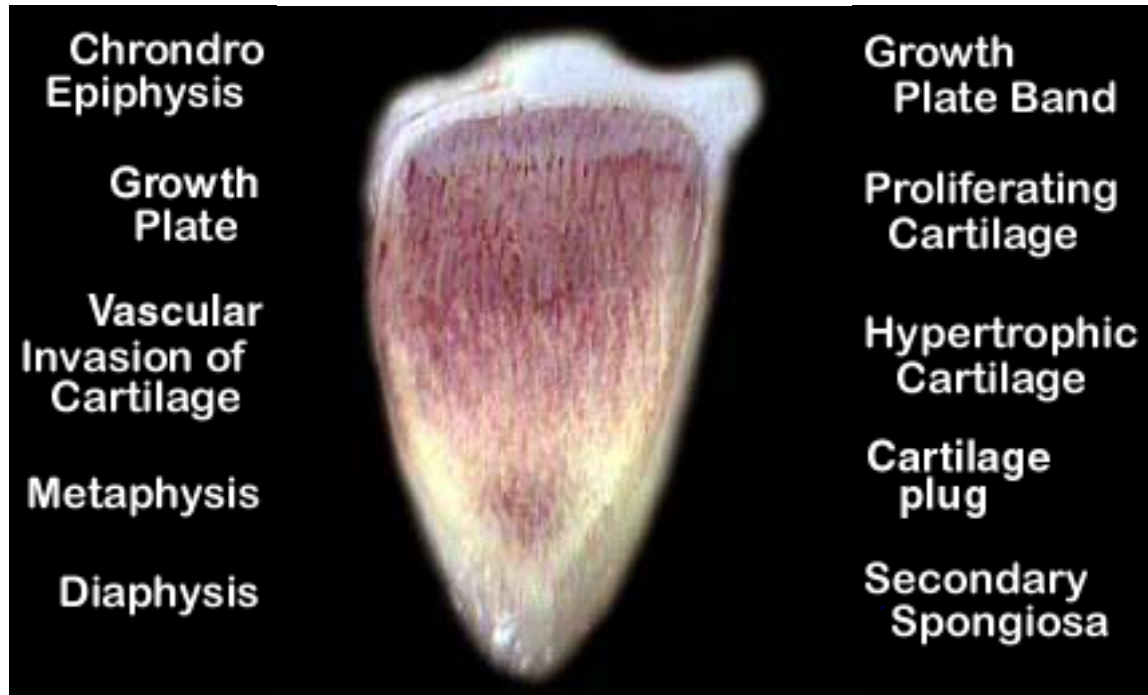
# Calcium/Vitamin D Rickets



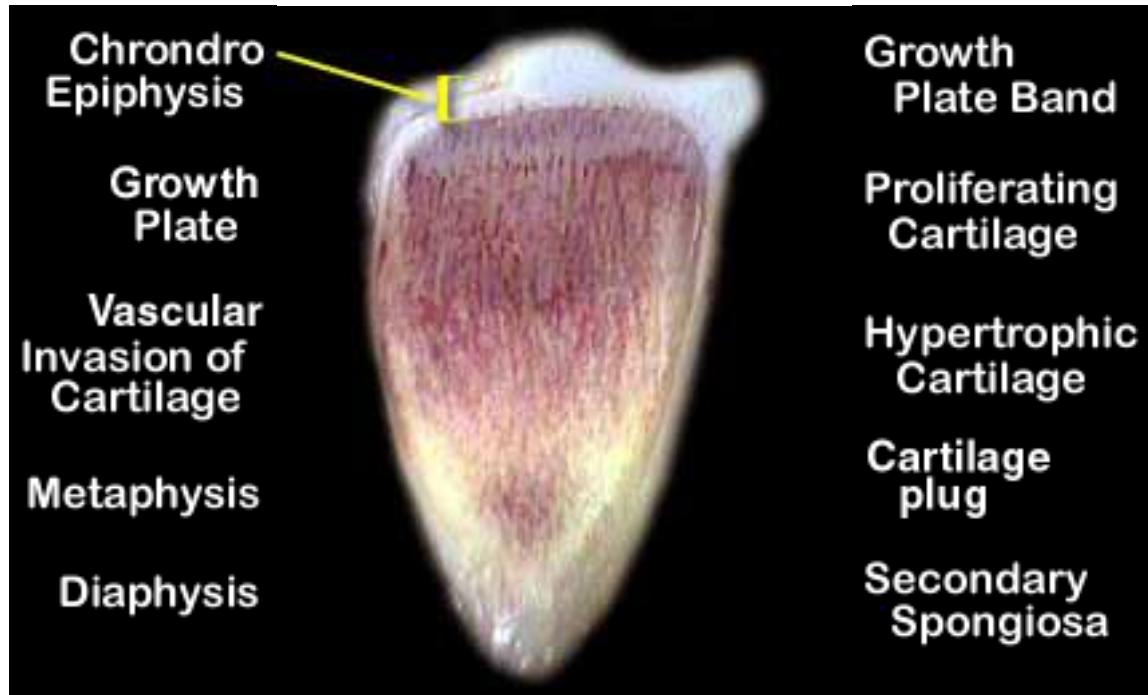
# Calcium/Vitamin D Rickets



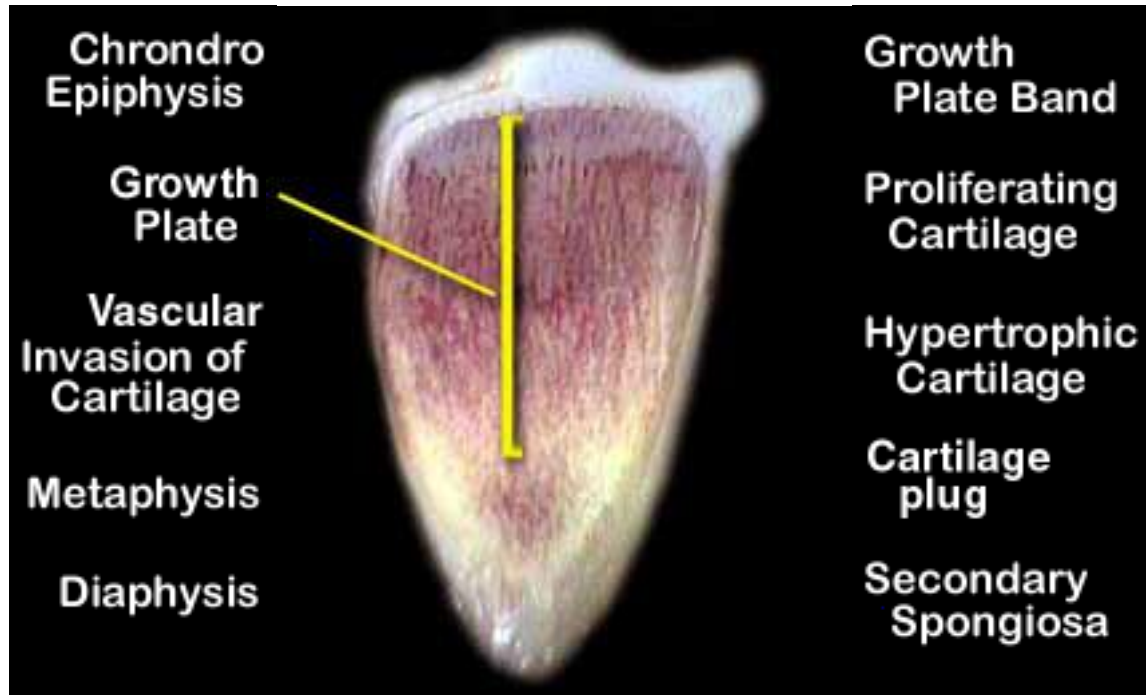
# Phosphorus Rickets



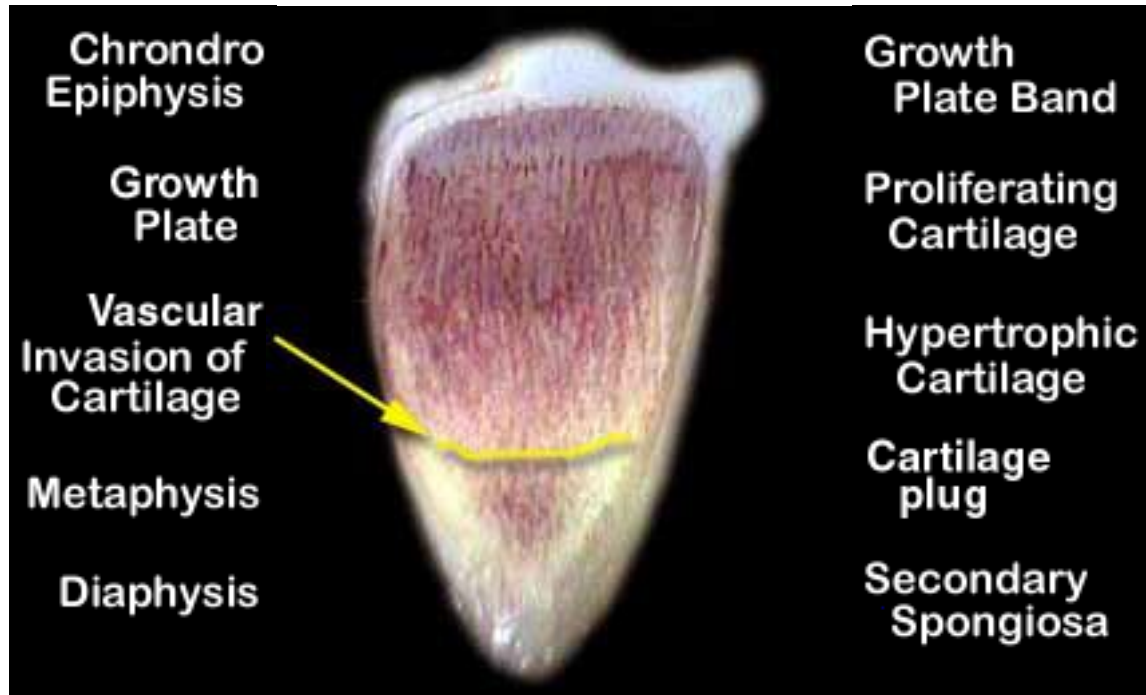
# Phosphorus Rickets



# Phosphorus Rickets

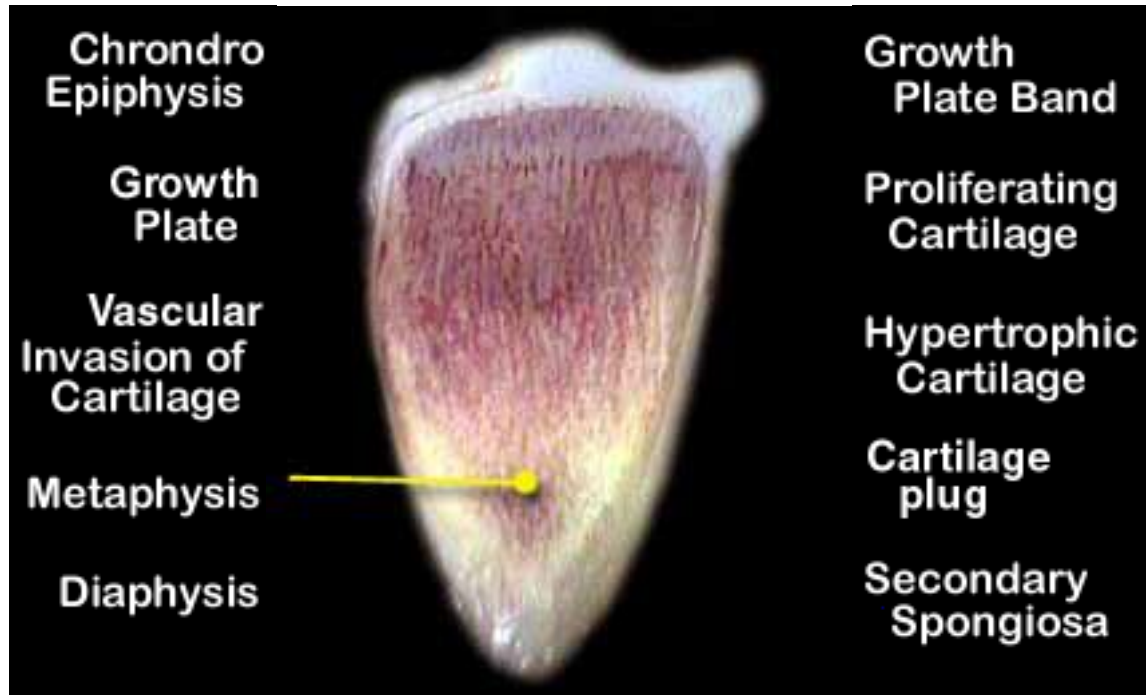


# Phosphorus Rickets

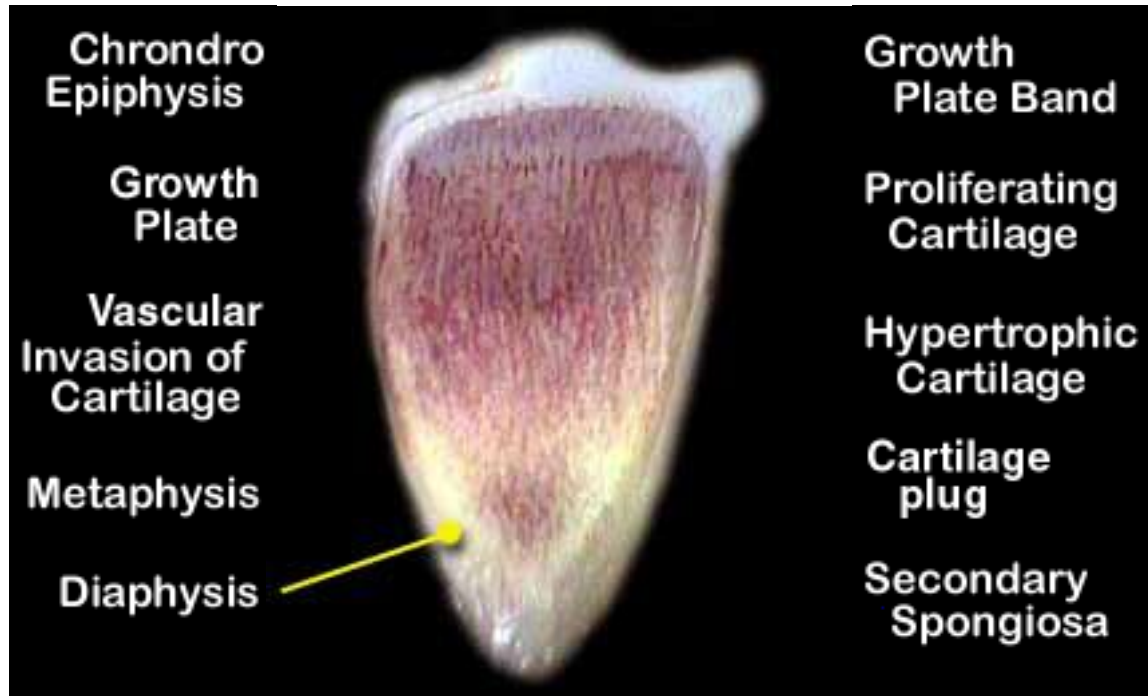




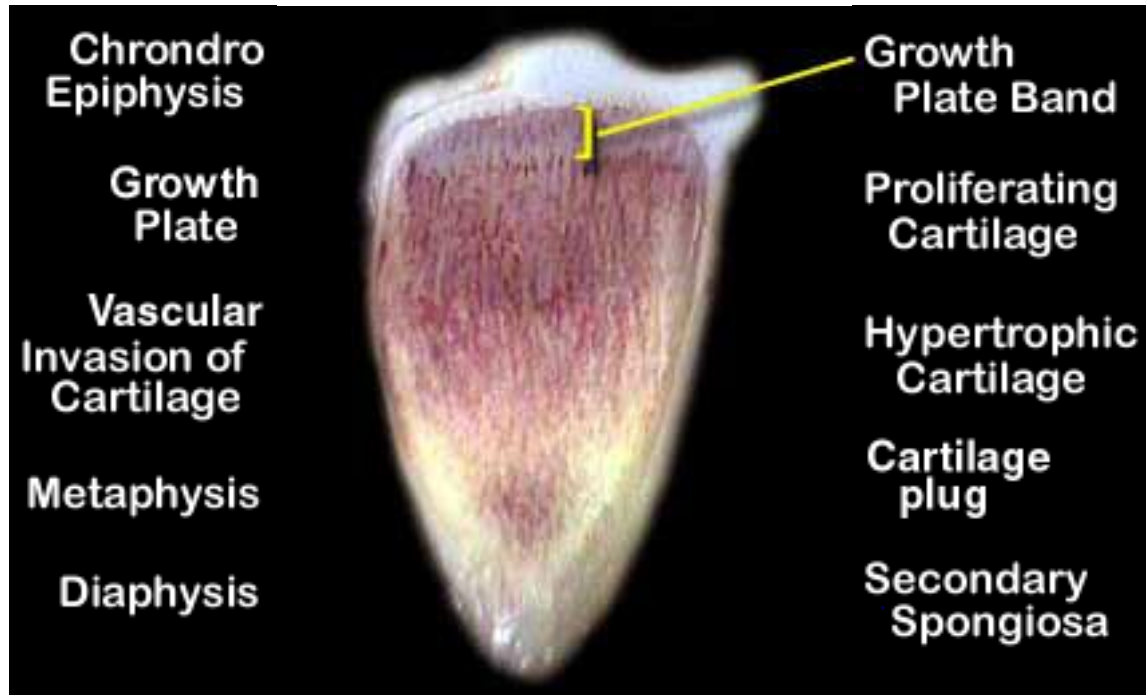
# Phosphorus Rickets



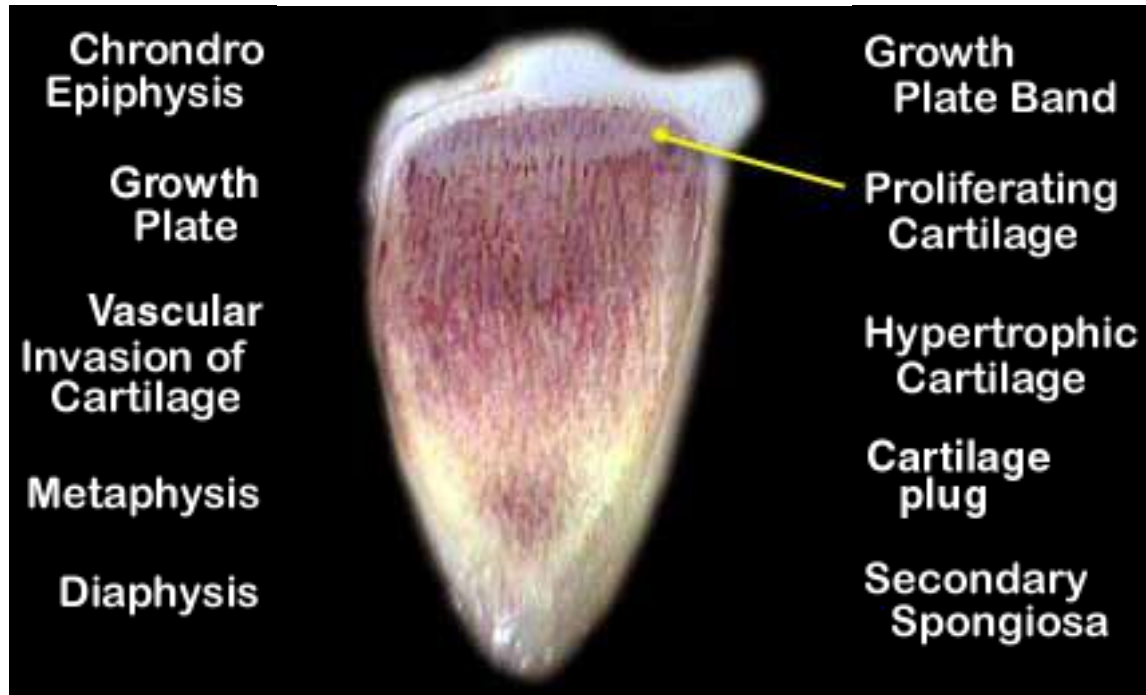
# Phosphorus Rickets



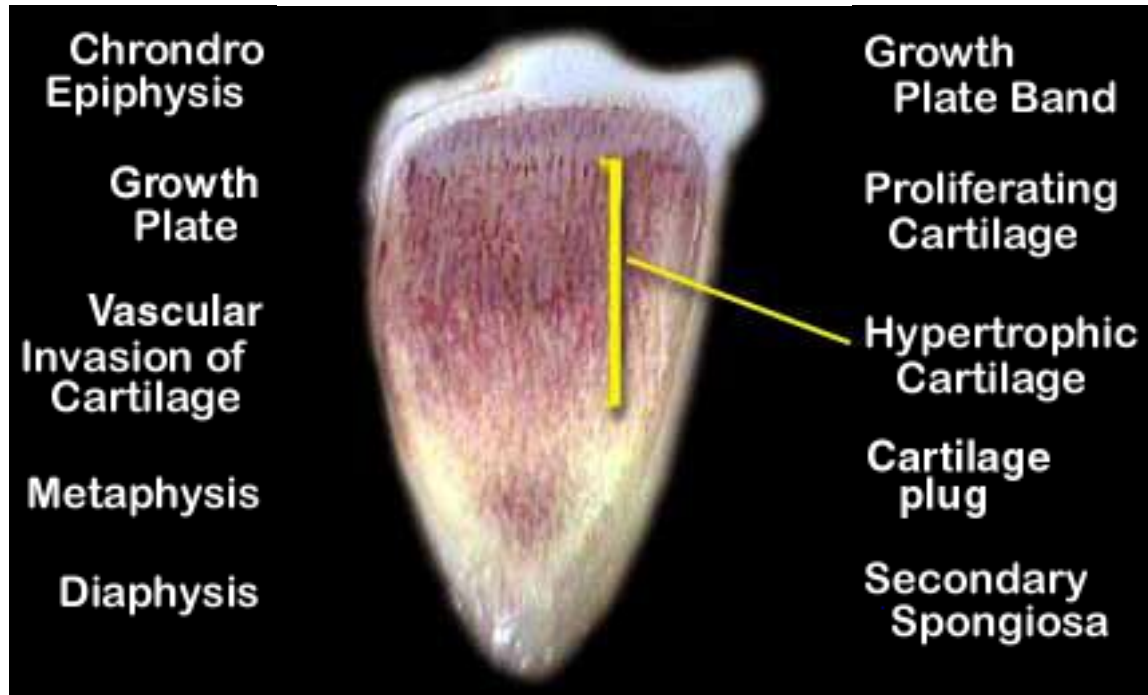
# Phosphorus Rickets



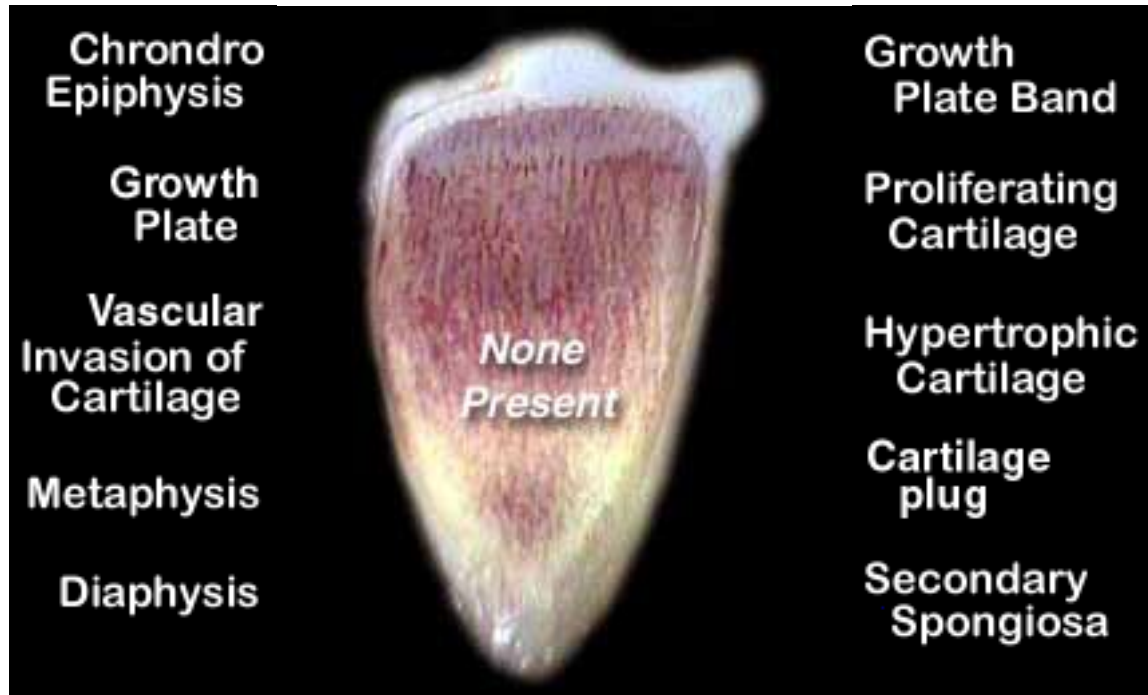
# Phosphorus Rickets



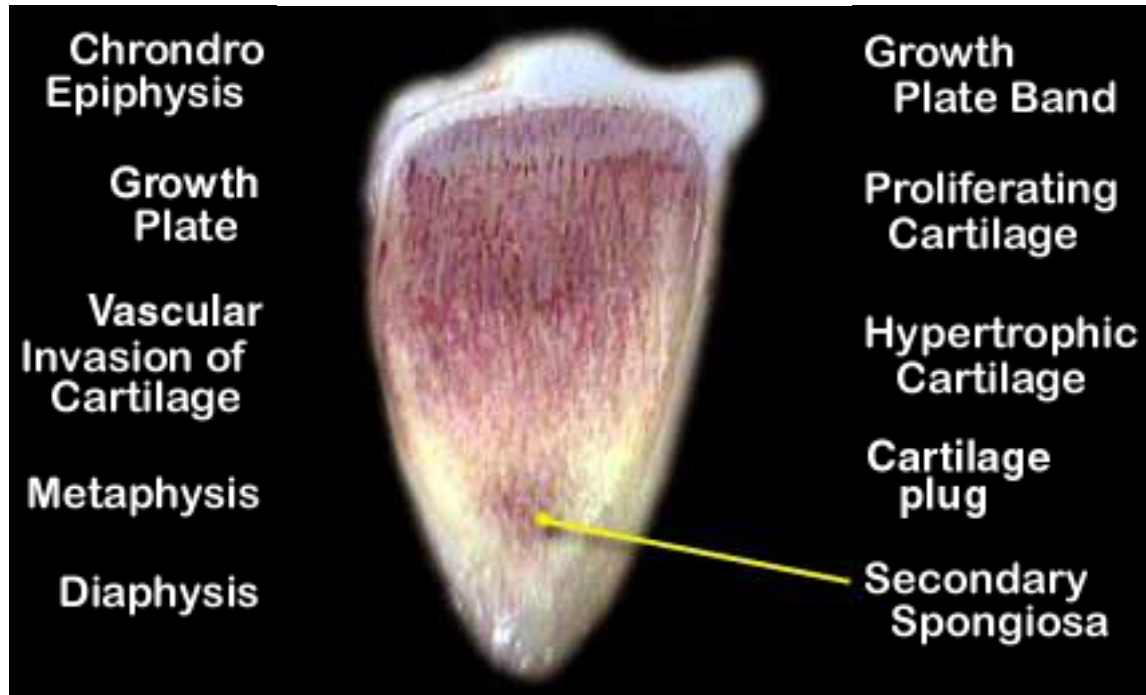
# Phosphorus Rickets



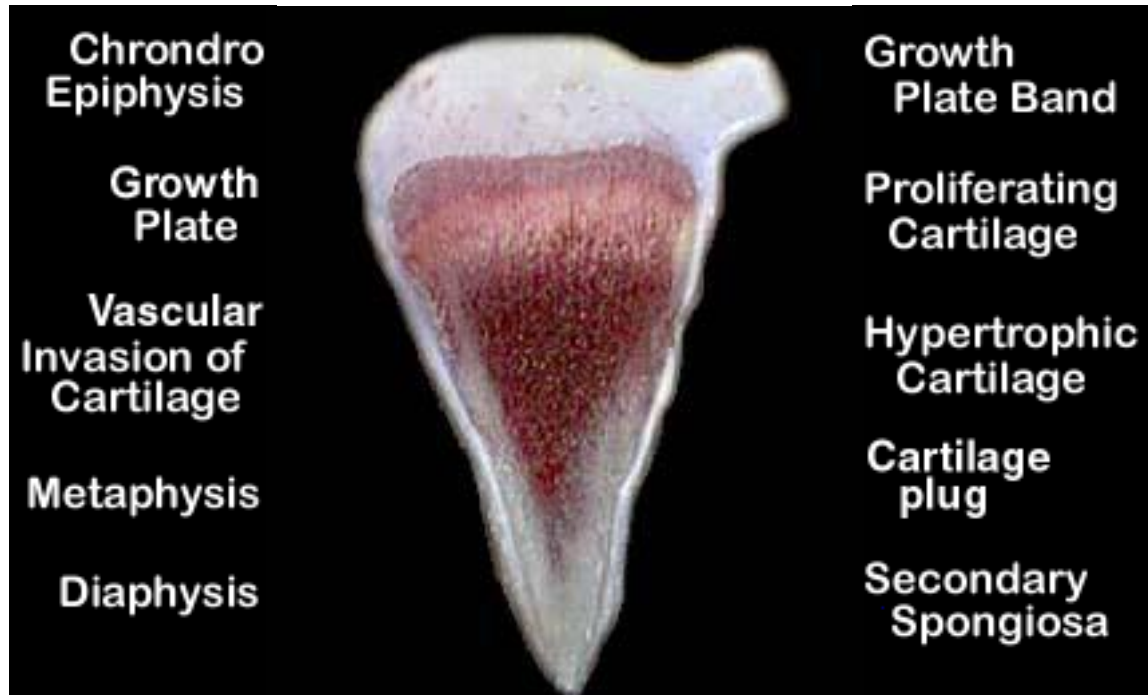
# Phosphorus Rickets



# Phosphorus Rickets

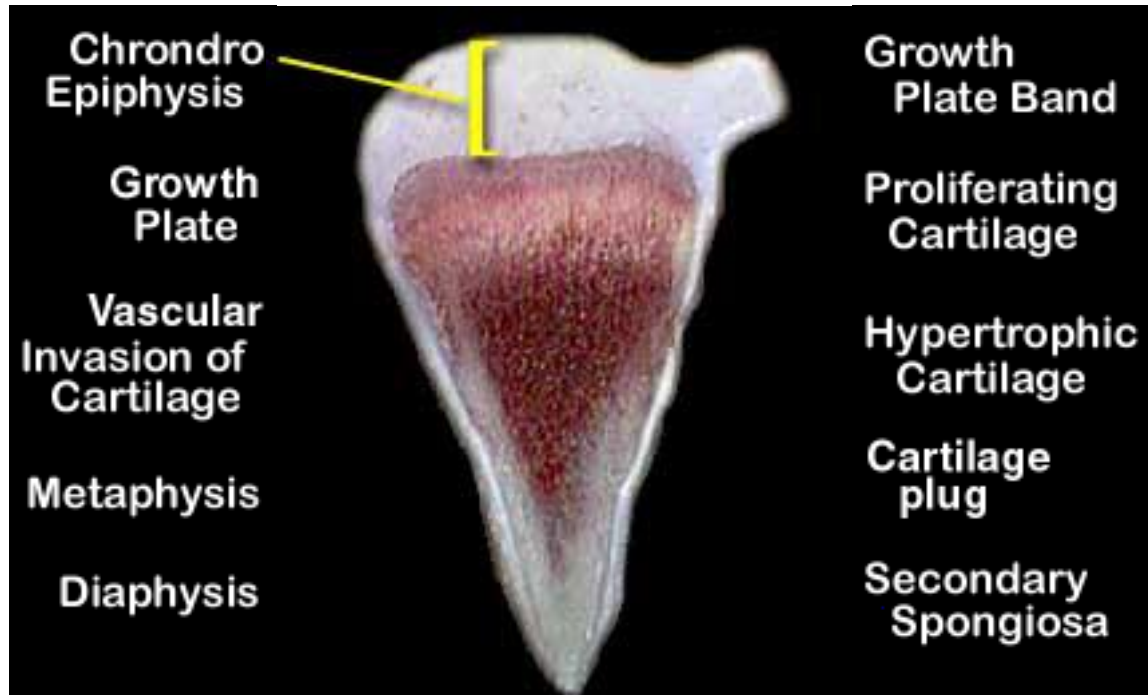


# Normal

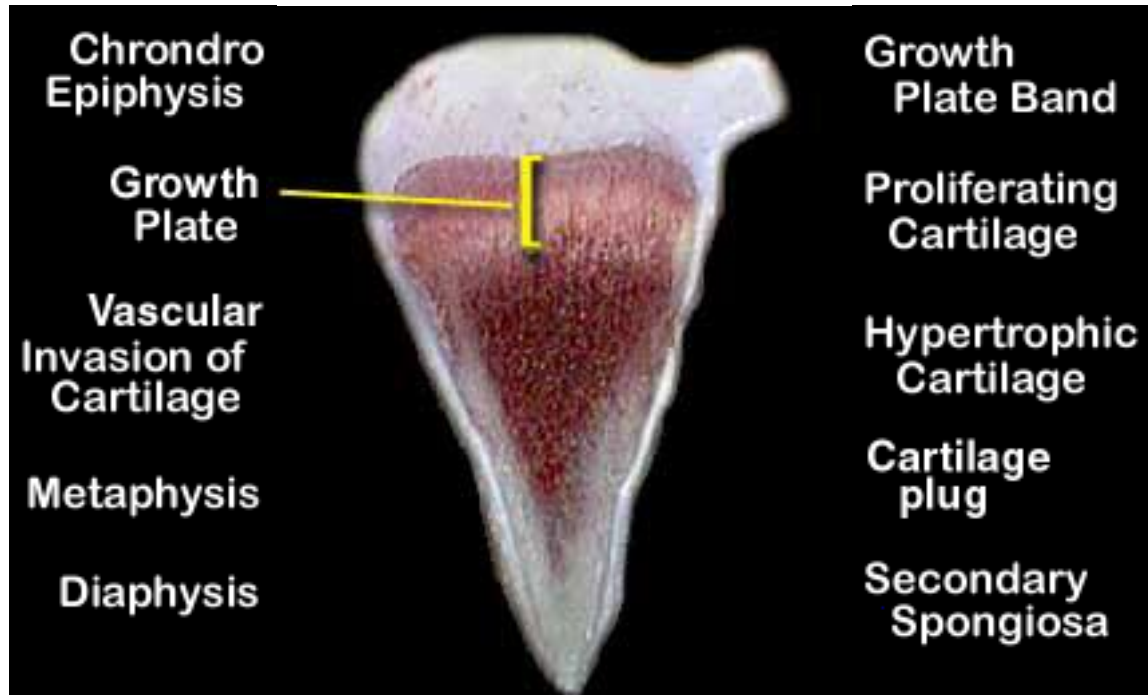




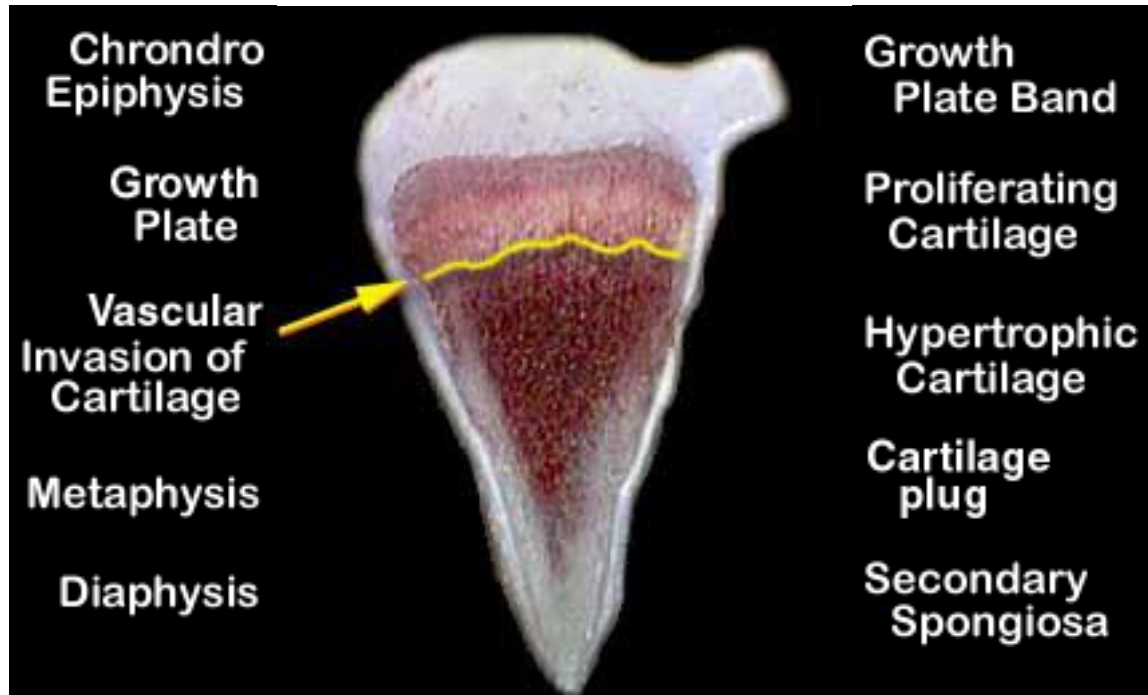
# Normal



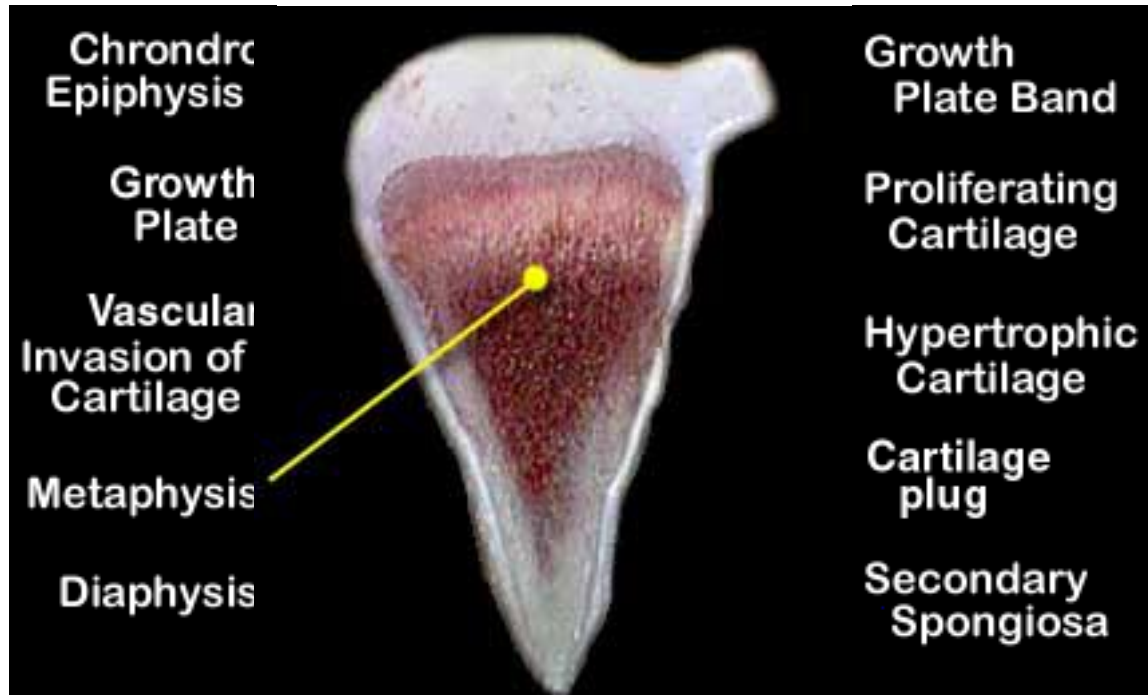
# Normal



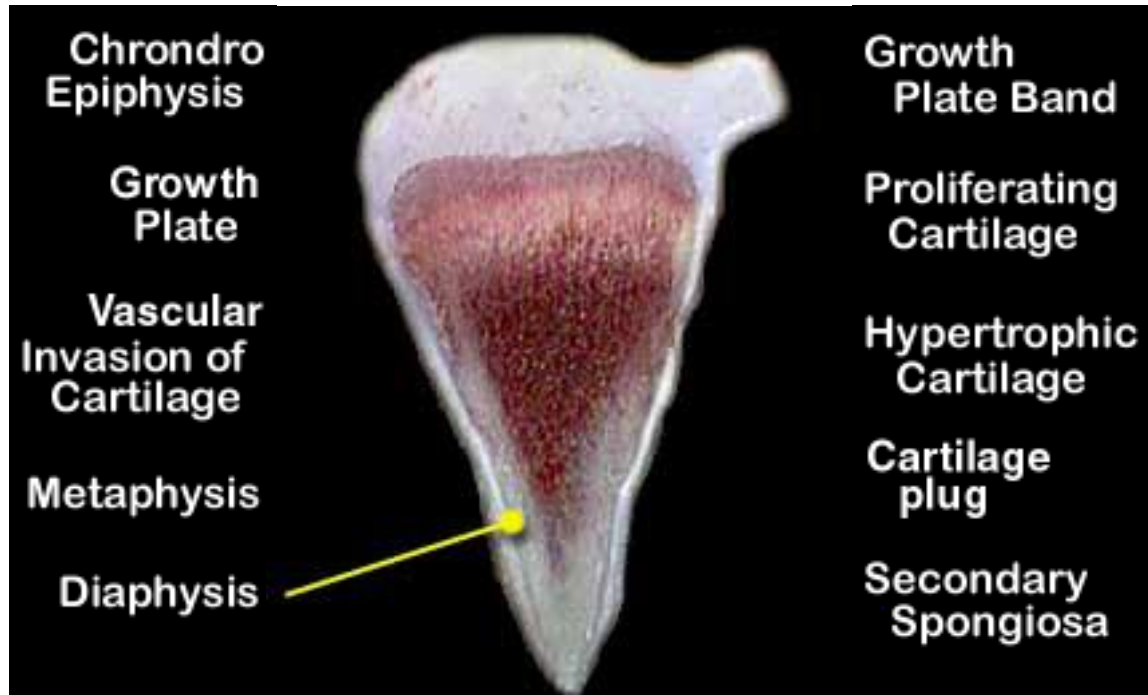
# Normal



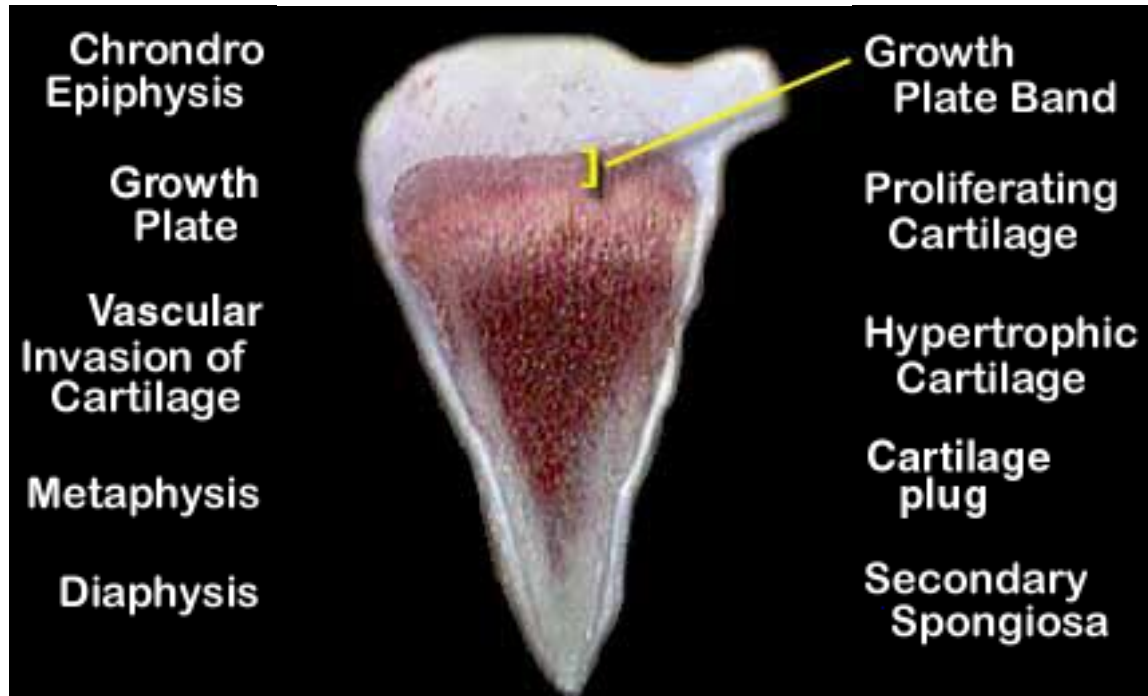
# Normal



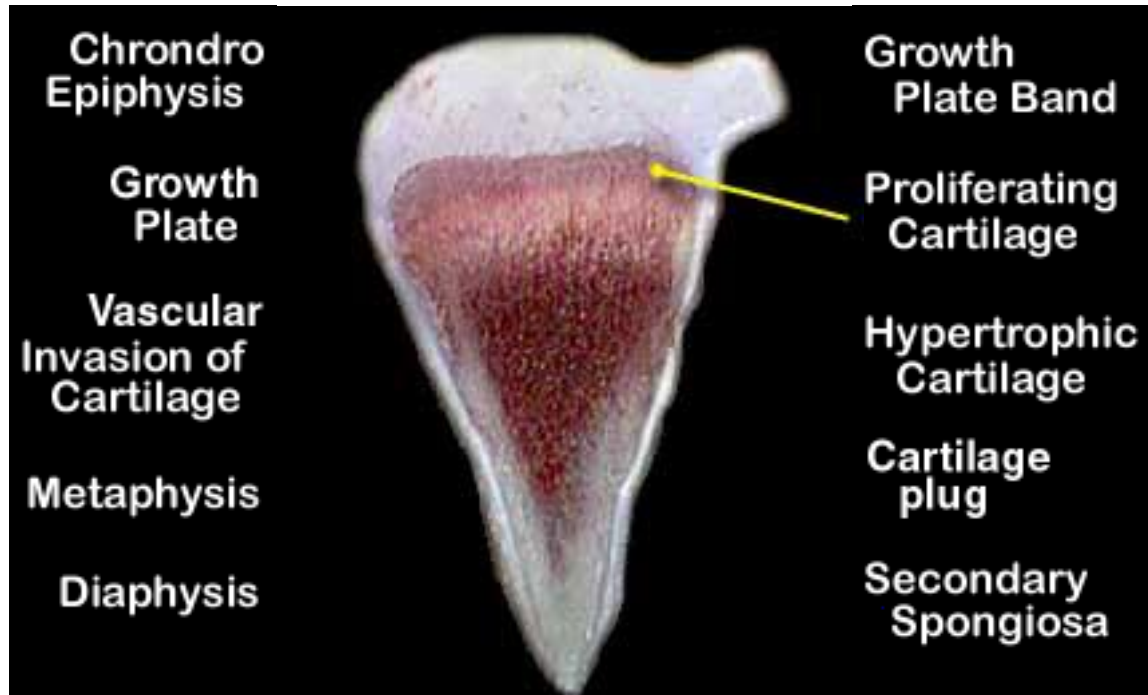
# Normal



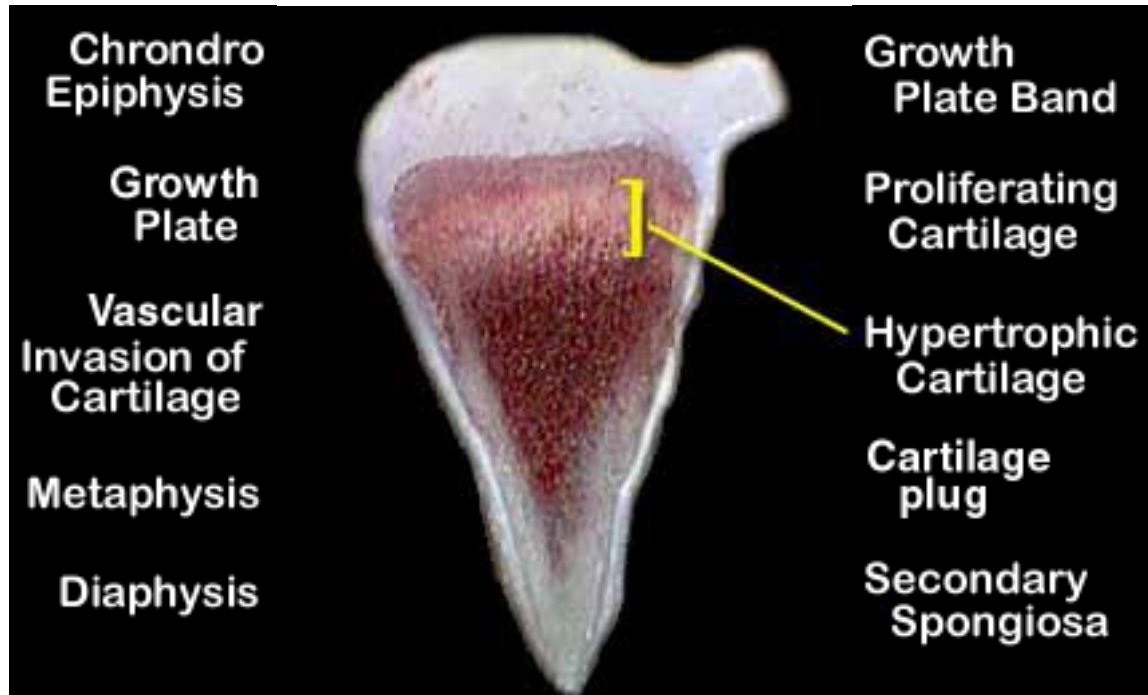
# Normal



# Normal

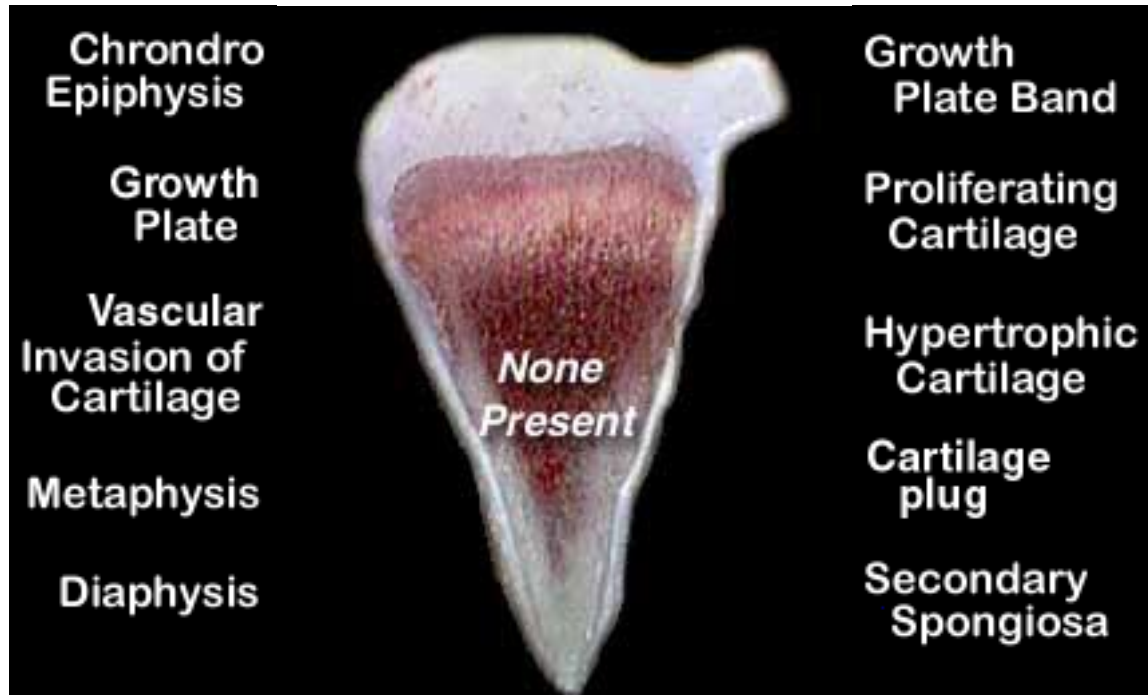


# Normal

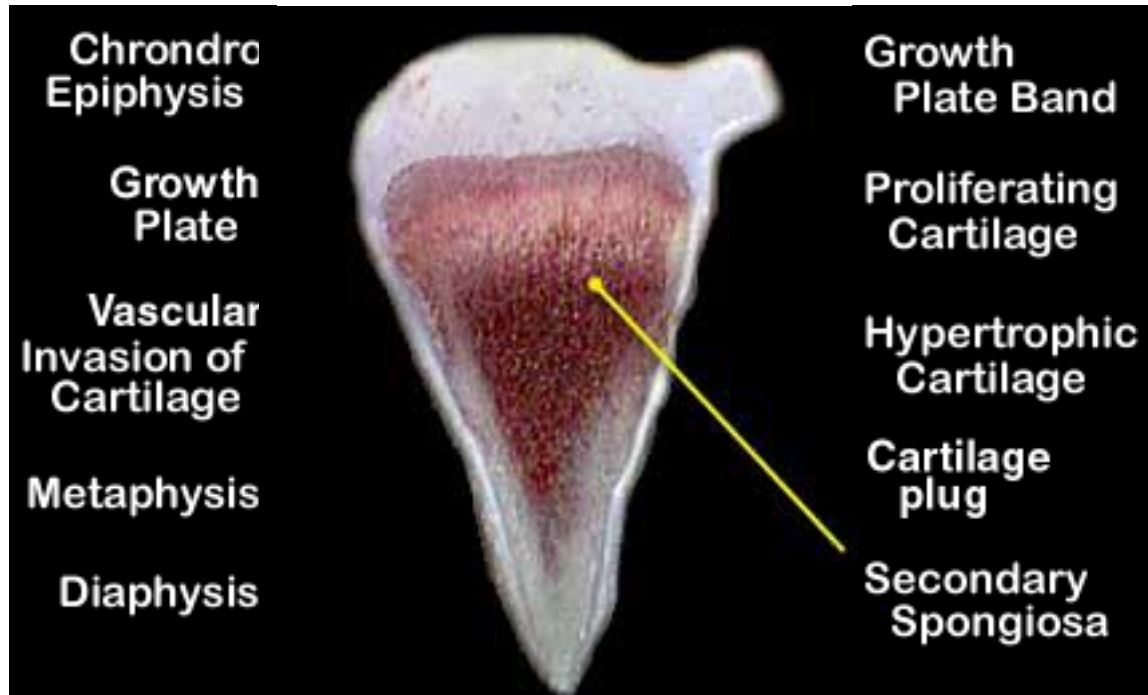




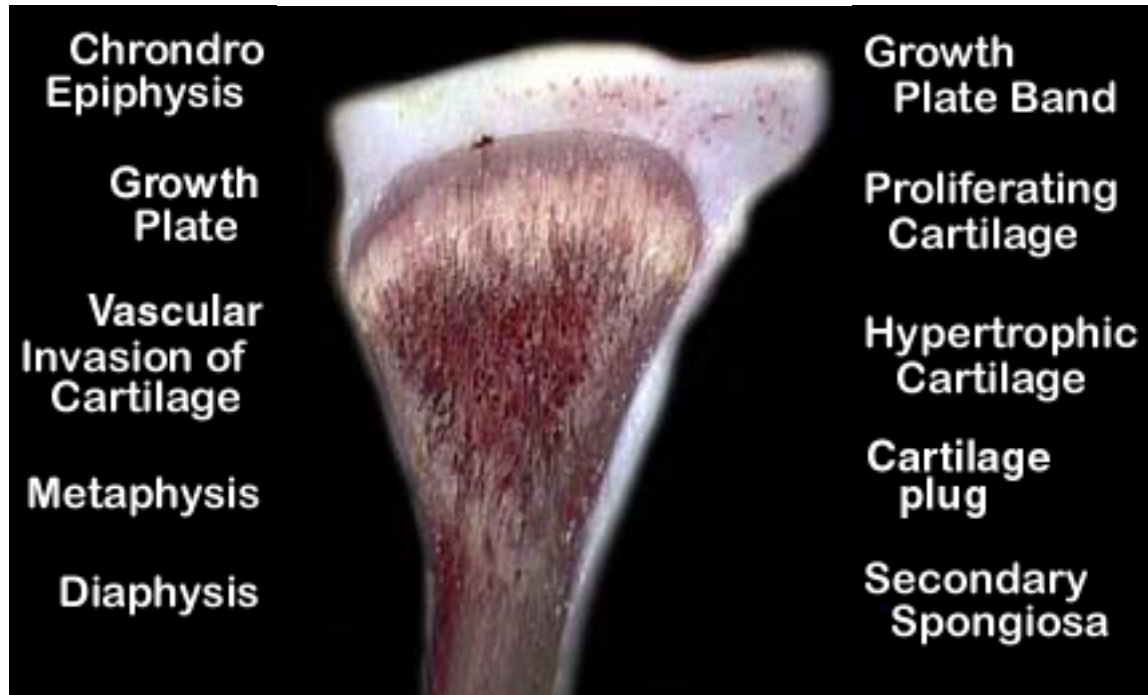# Normal



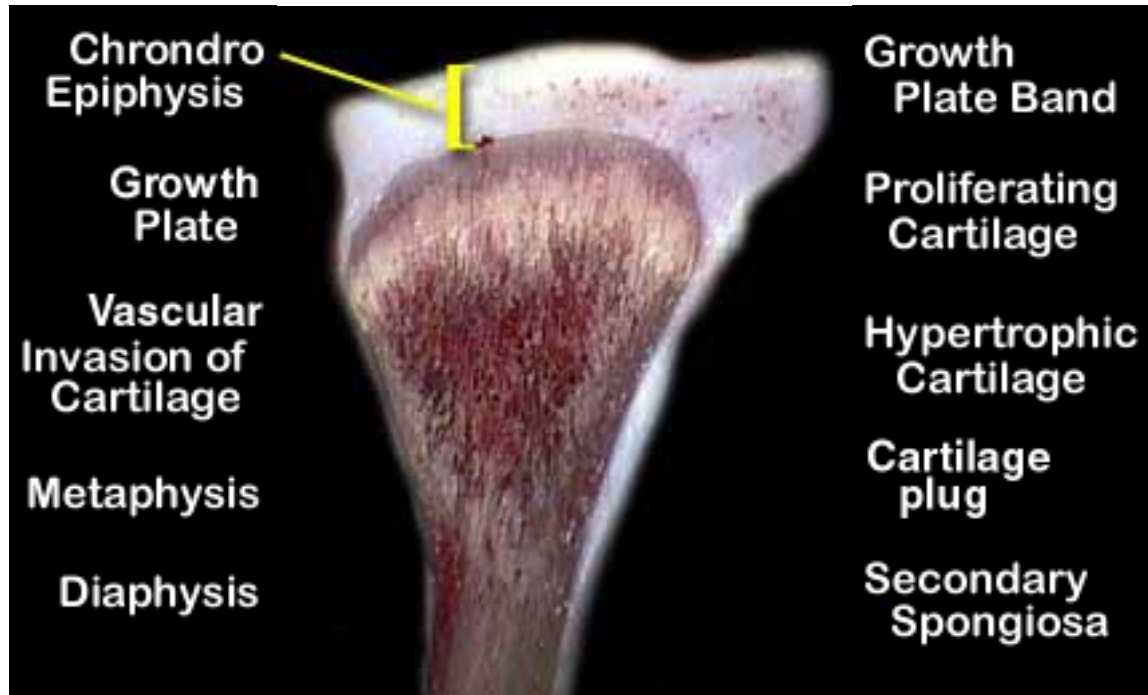
# Normal



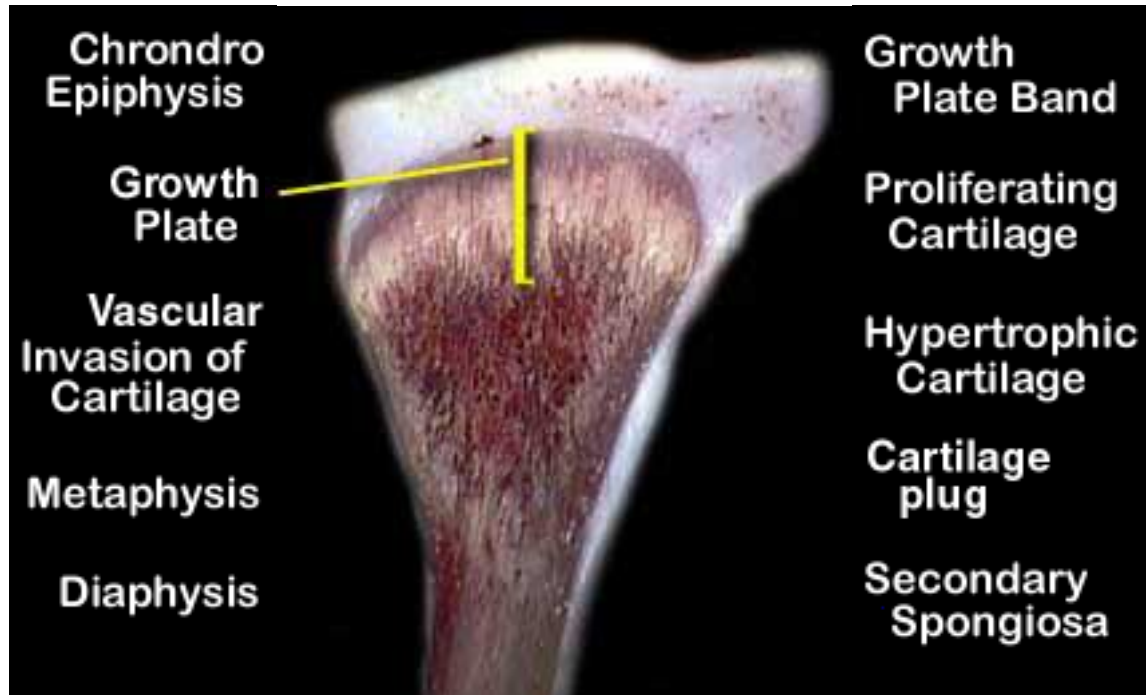
## Tibial Dyschondroplasia (Score 1)



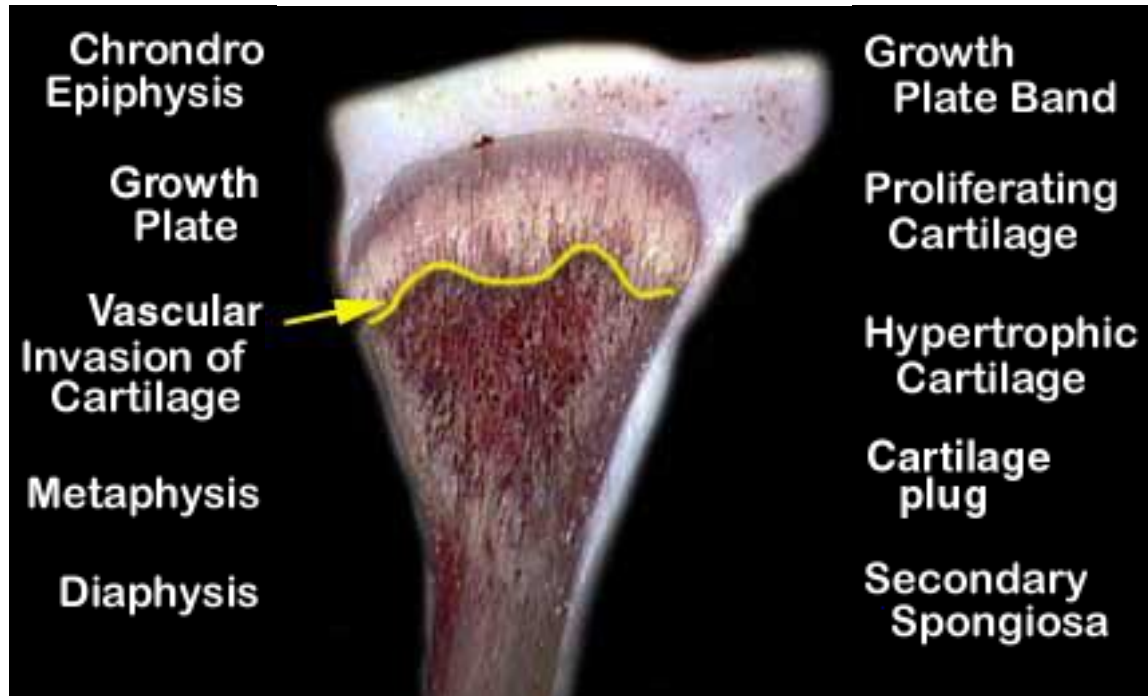
## Tibial Dyschondroplasia (Score 1)



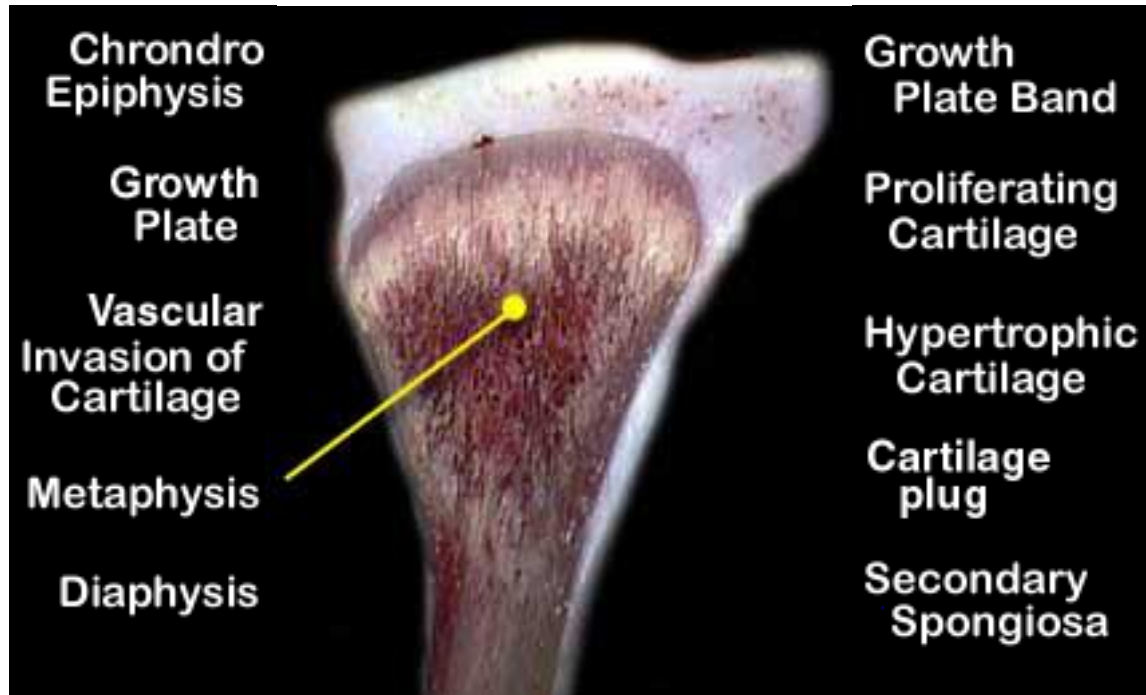
## Tibial Dyschondroplasia (Score 1)



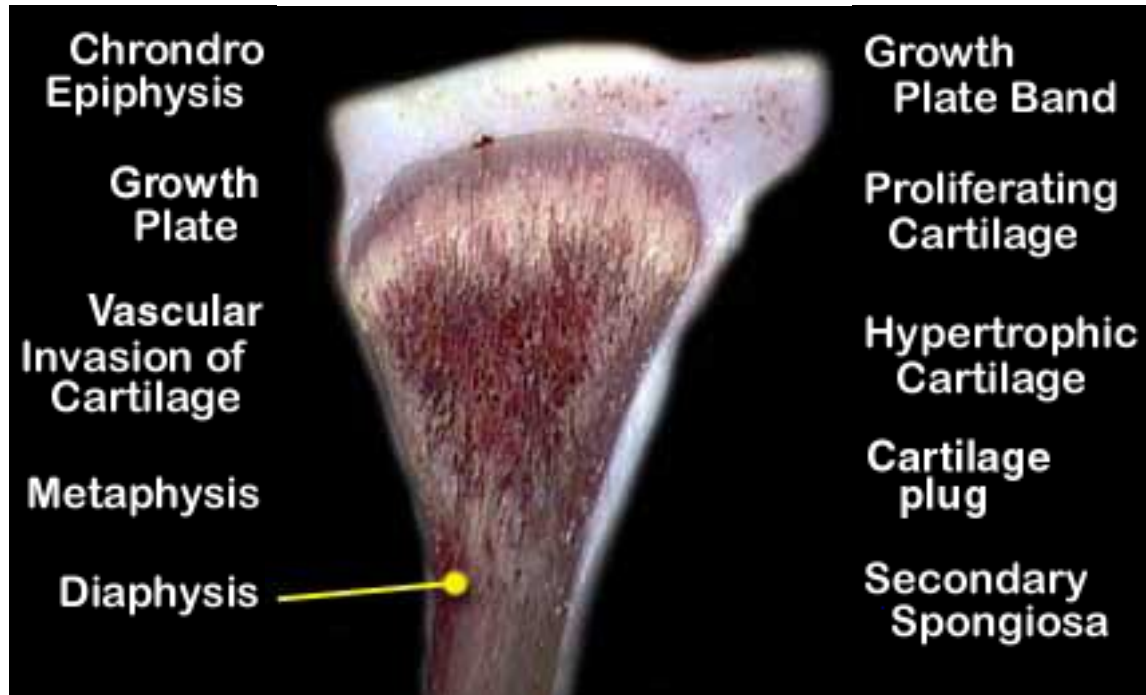
## Tibial Dyschondroplasia (Score 1)



## Tibial Dyschondroplasia (Score 1)

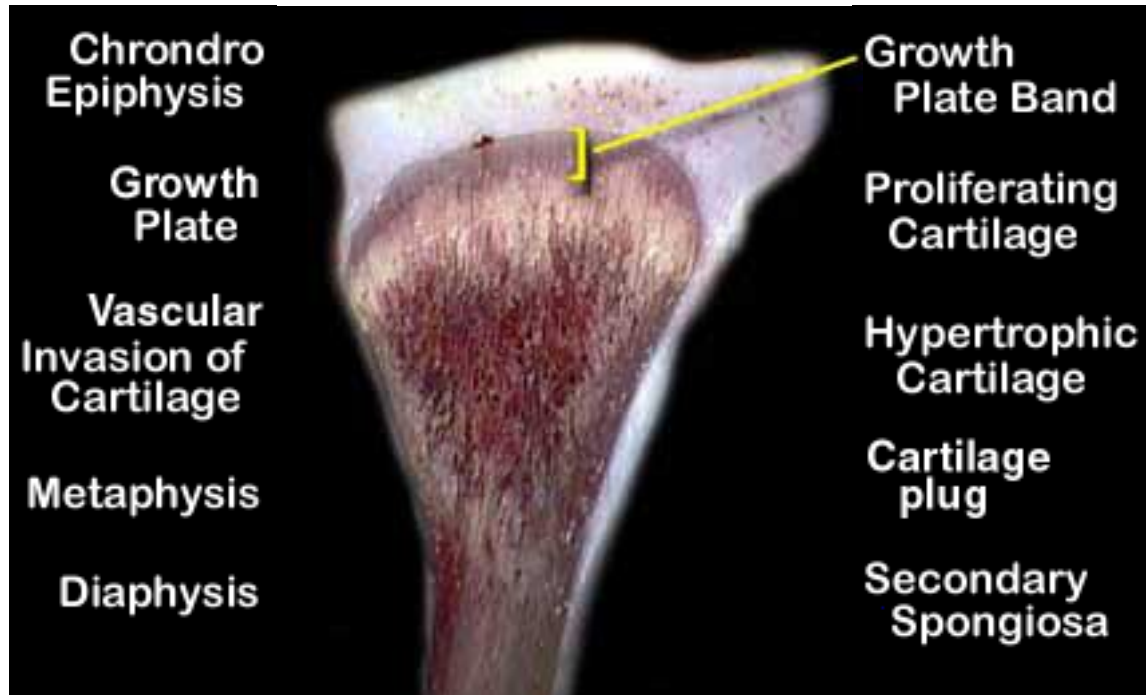


## Tibial Dyschondroplasia (Score 1)

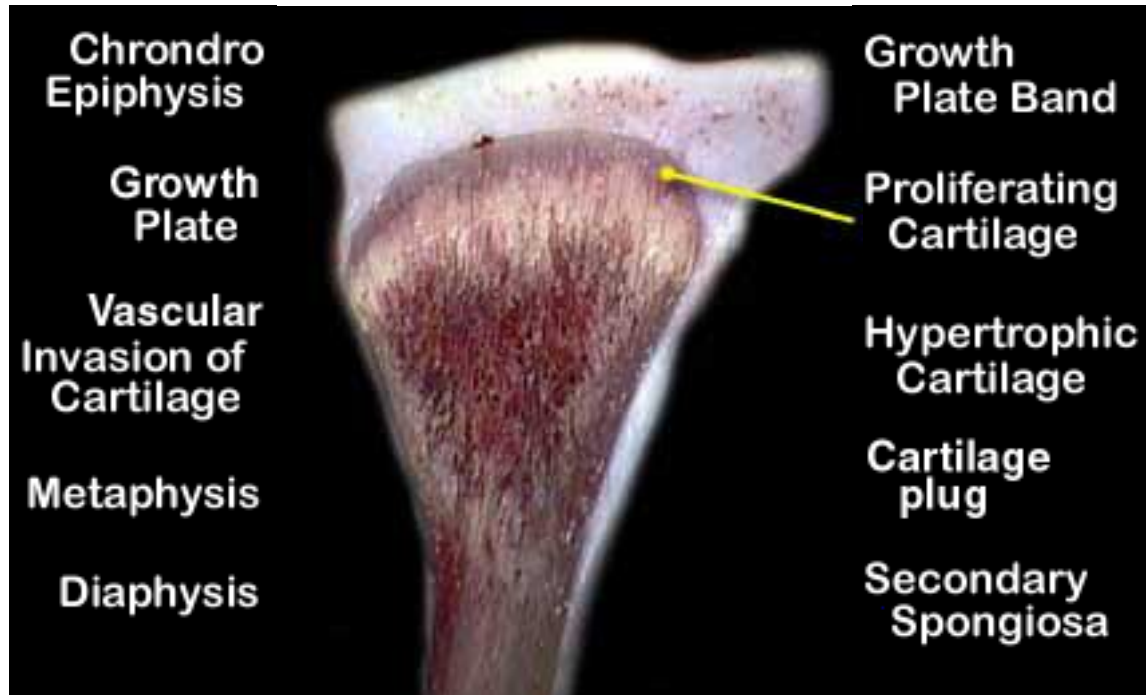




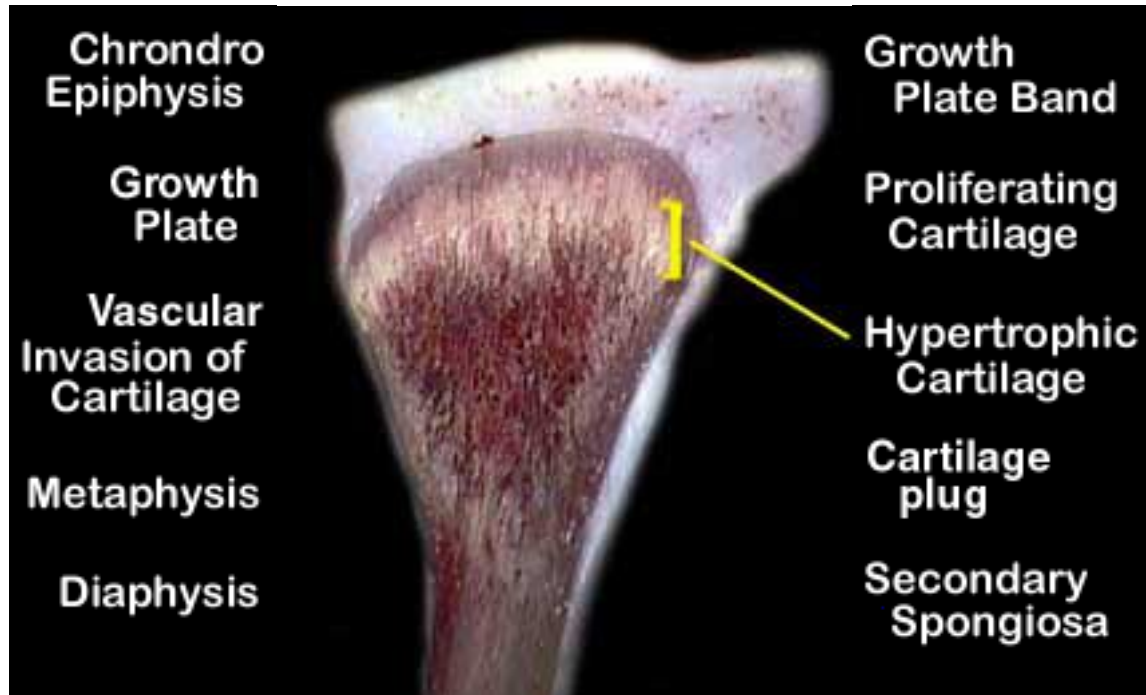
## Tibial Dyschondroplasia (Score 1)



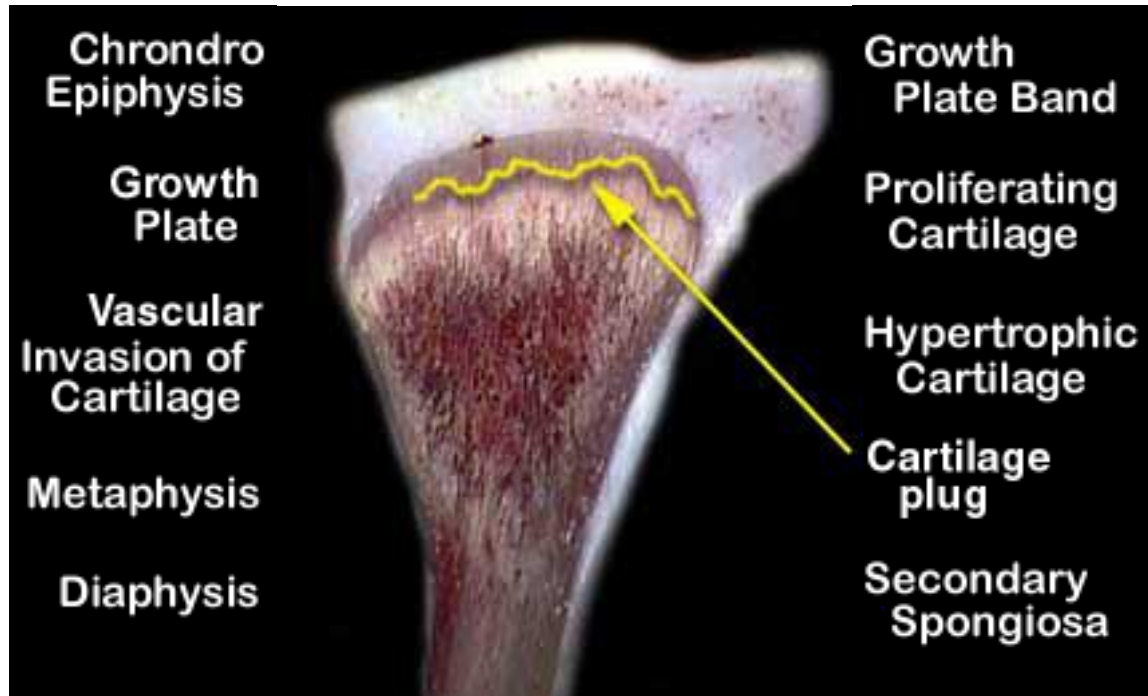
## Tibial Dyschondroplasia (Score 1)



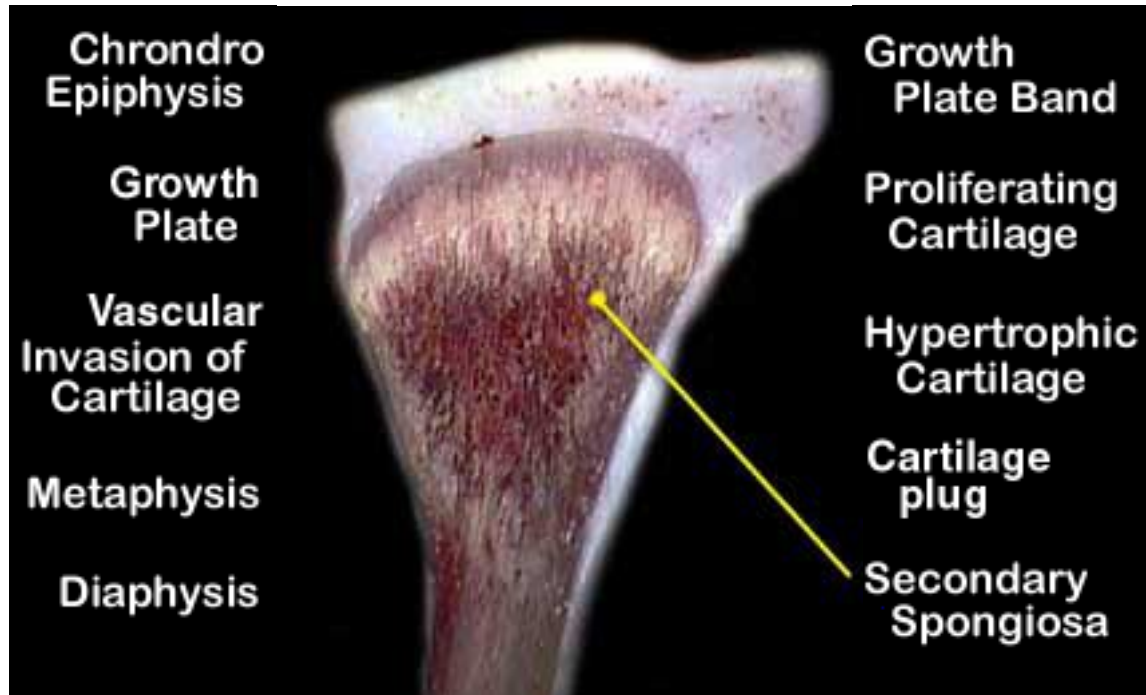
## Tibial Dyschondroplasia (Score 1)



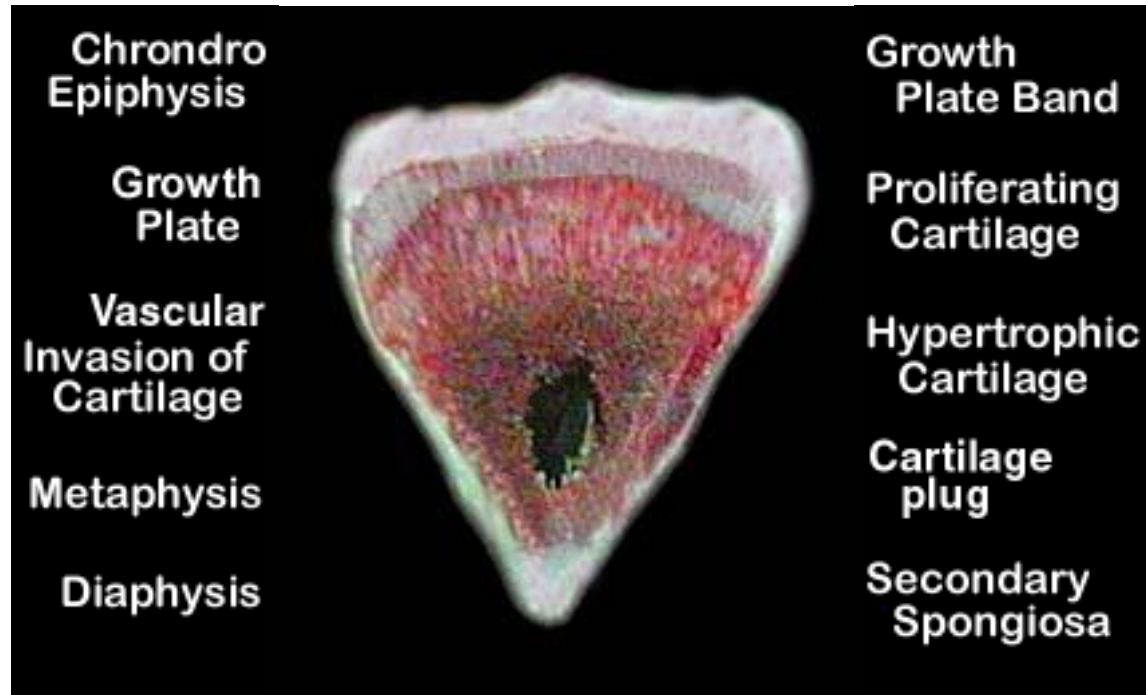
## Tibial Dyschondroplasia (Score 1)



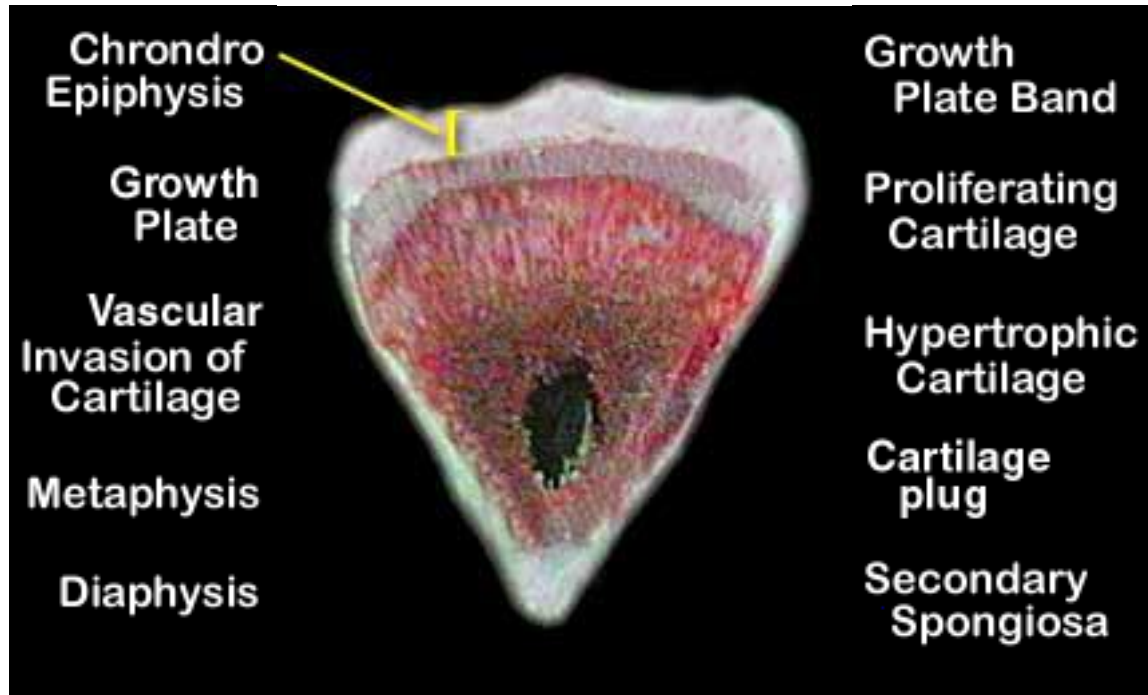
## Tibial Dyschondroplasia (Score 1)



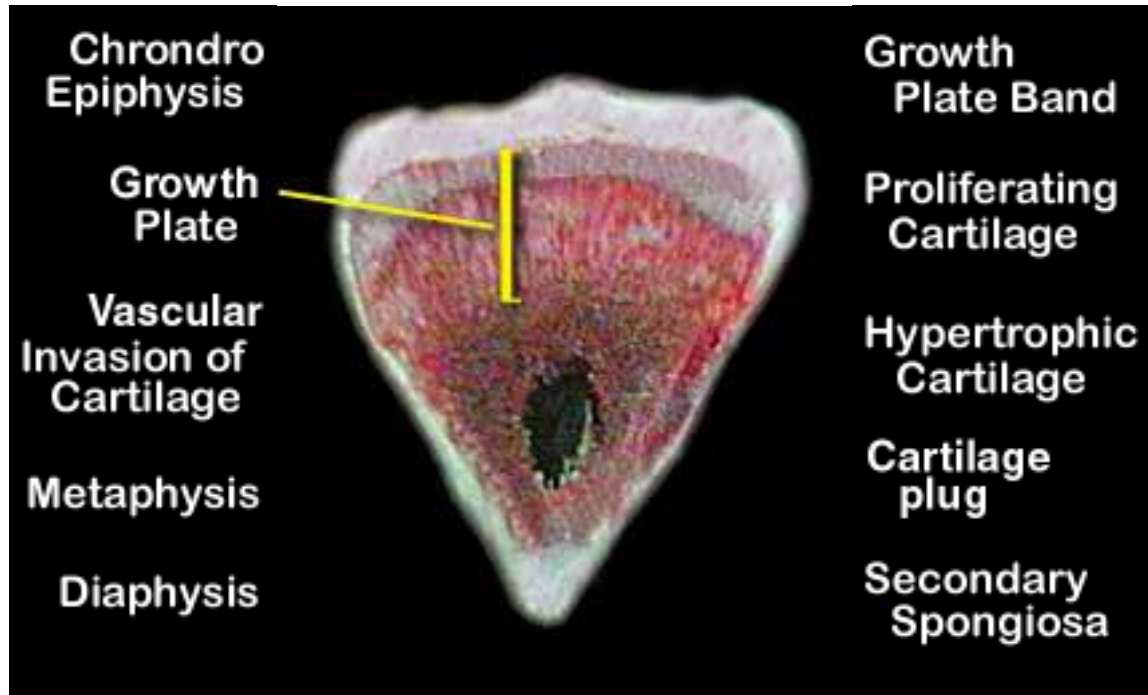
## Tibial Dyschondroplasia (Score 2)



## Tibial Dyschondroplasia (Score 2)

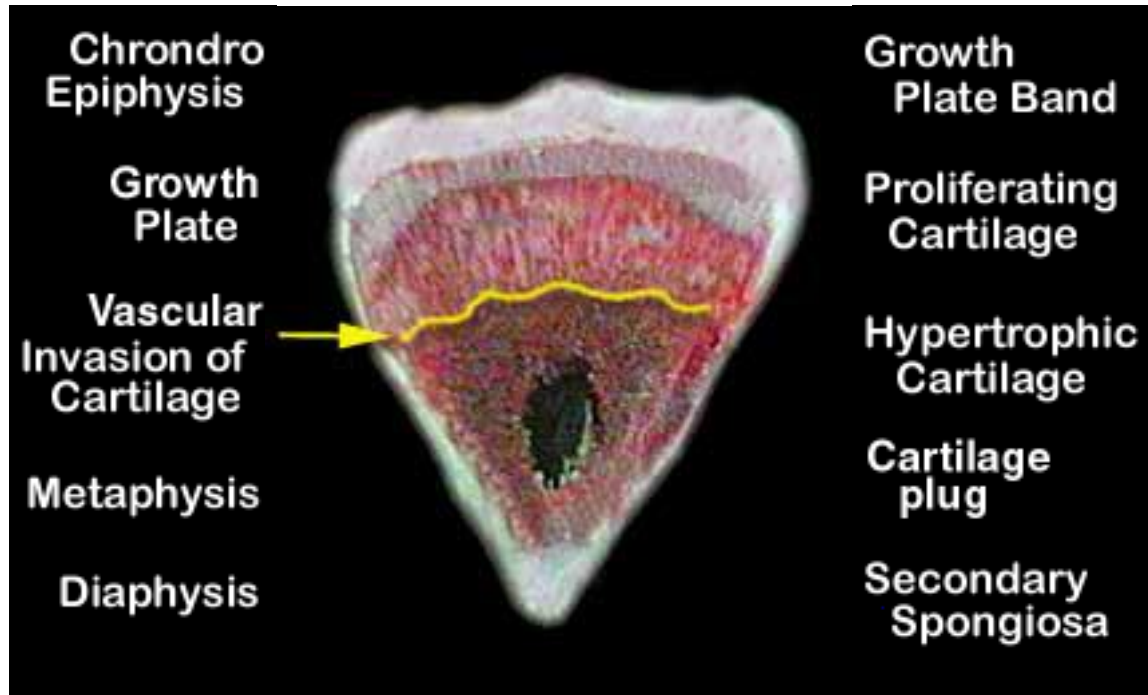


## Tibial Dyschondroplasia (Score 2)

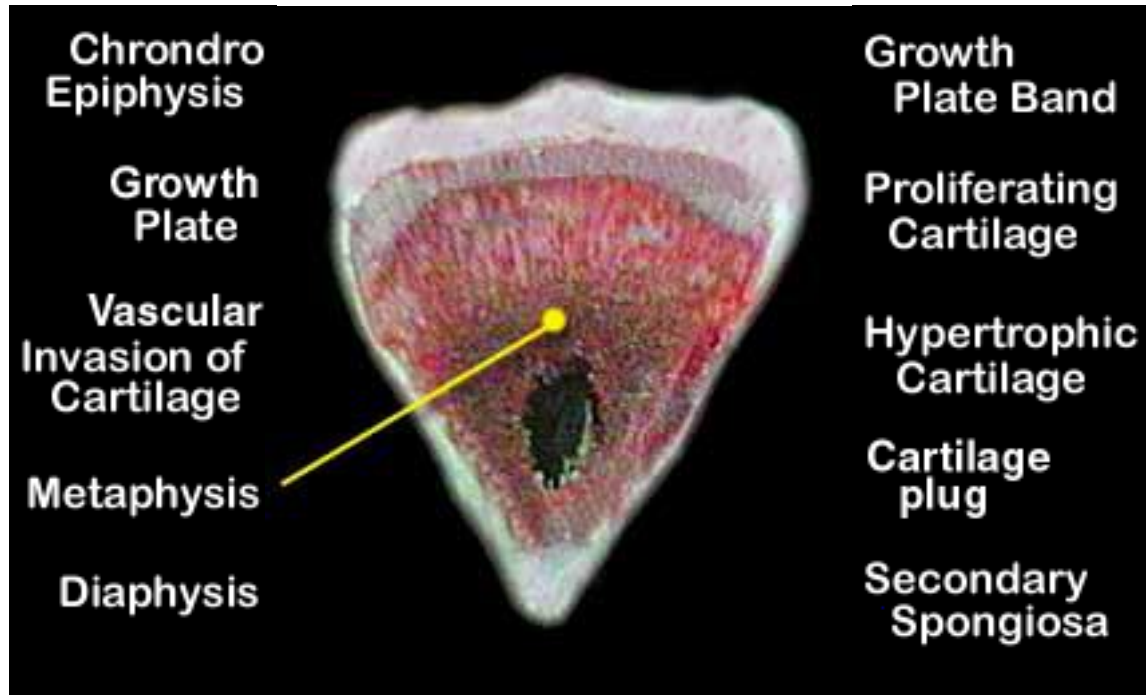




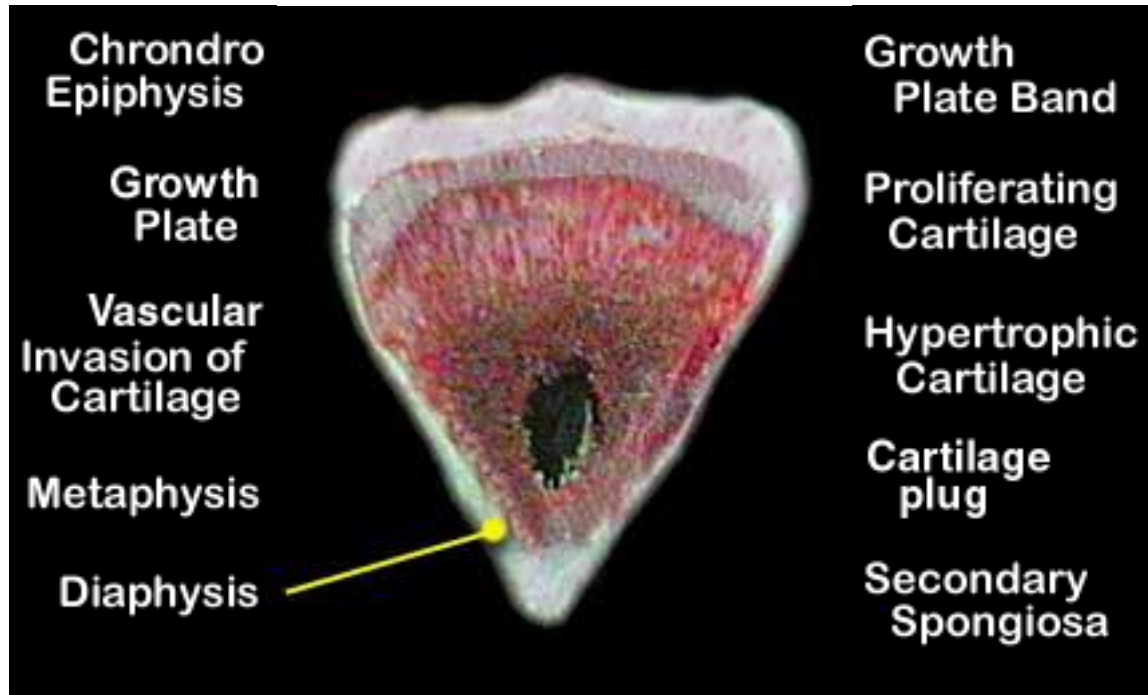
## Tibial Dyschondroplasia (Score 2)



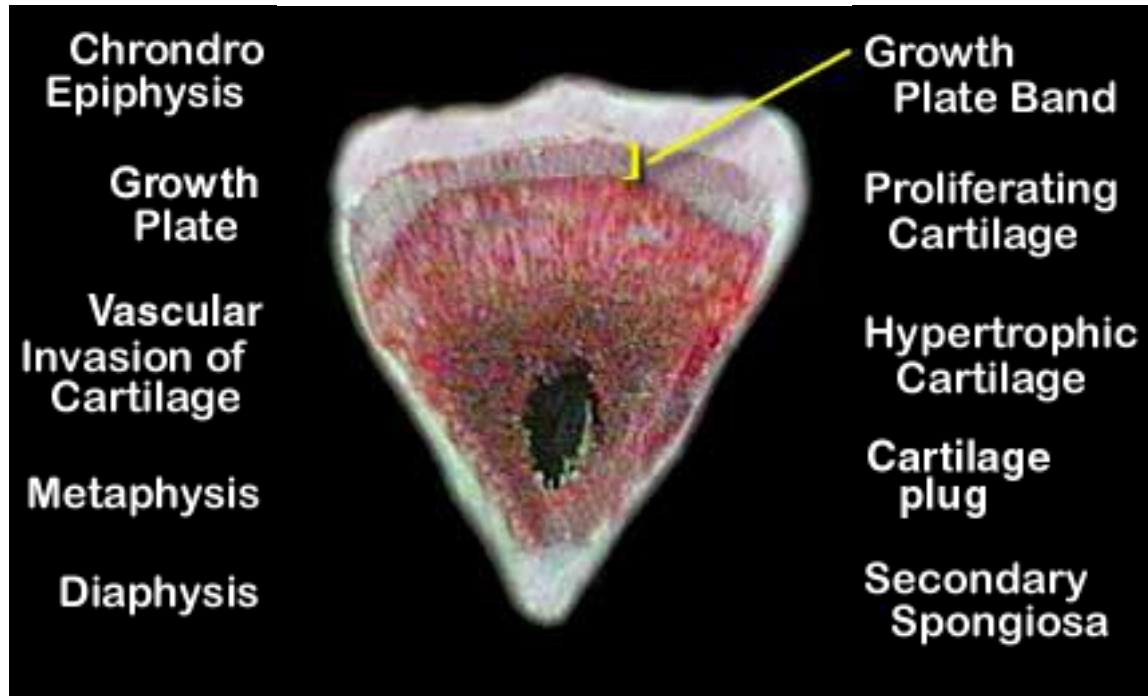
## Tibial Dyschondroplasia (Score 2)



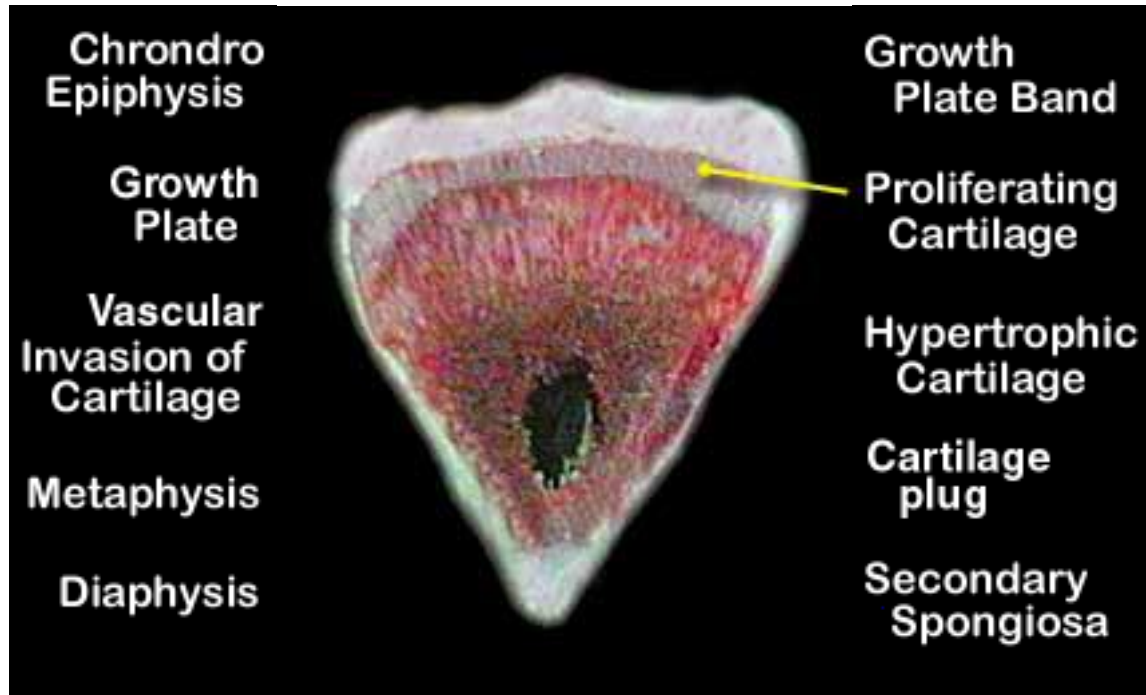
## Tibial Dyschondroplasia (Score 2)



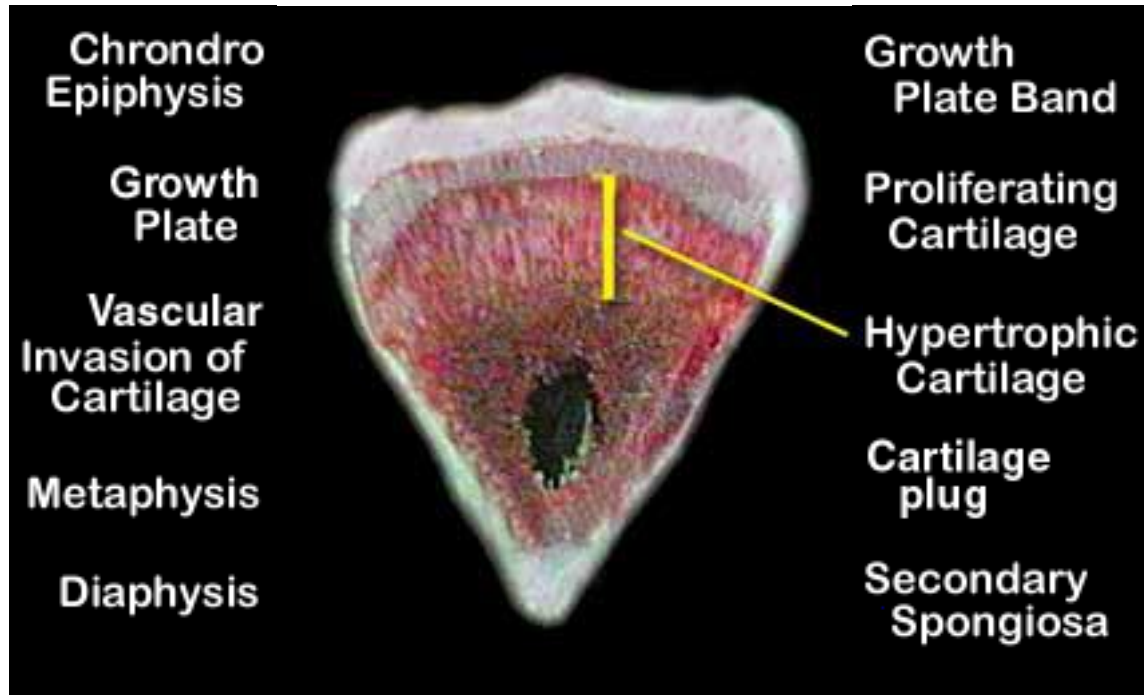
## Tibial Dyschondroplasia (Score 2)



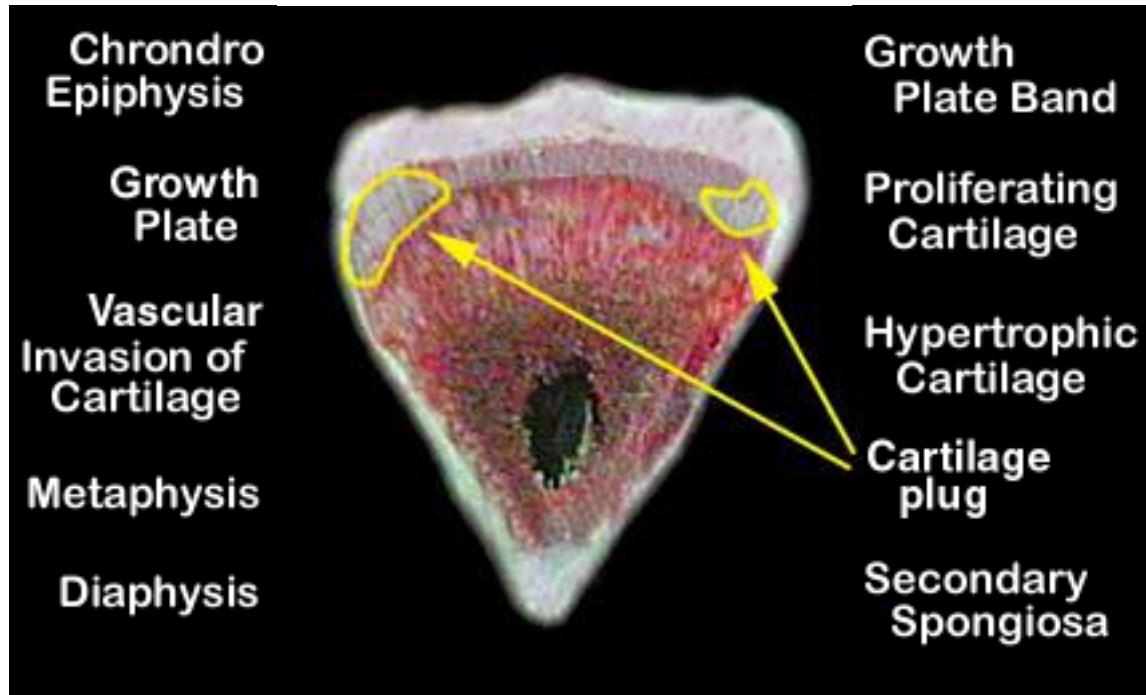
## Tibial Dyschondroplasia (Score 2)



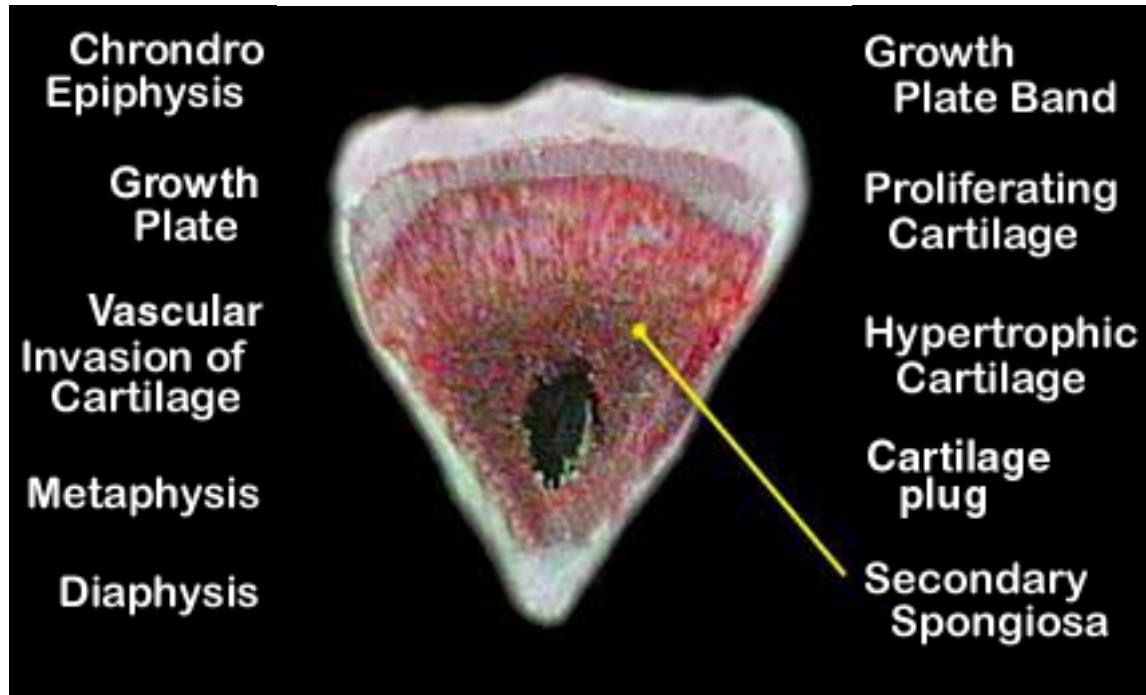
## Tibial Dyschondroplasia (Score 2)



## Tibial Dyschondroplasia (Score 2)

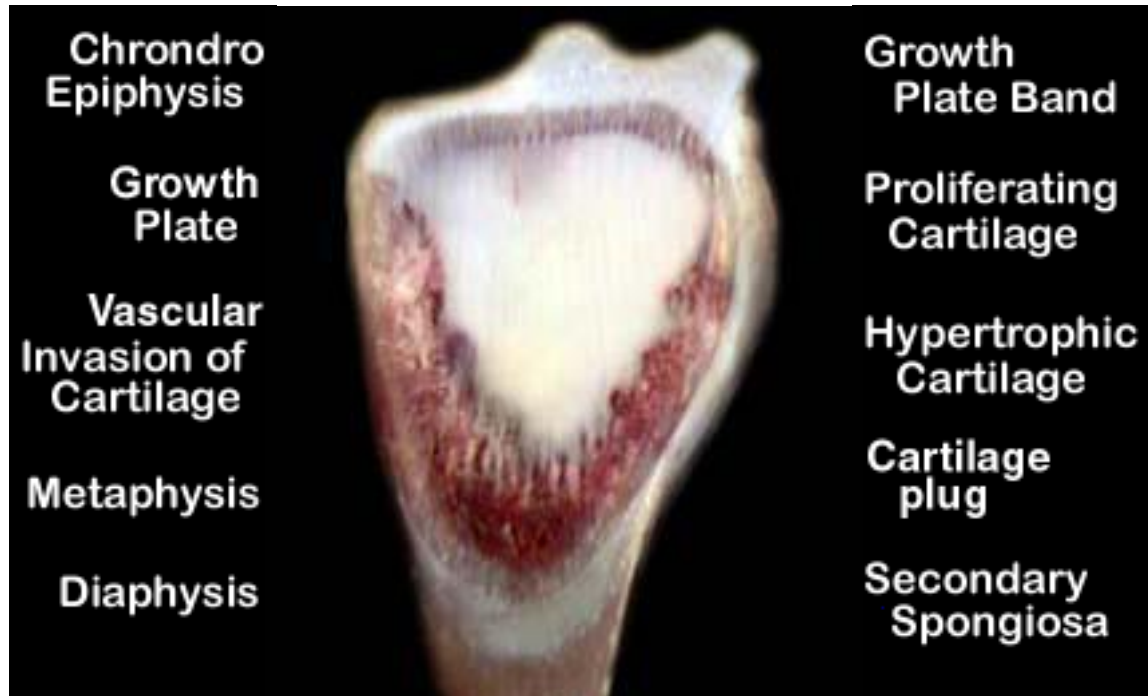

## Tibial Dyschondroplasia (Score 2)

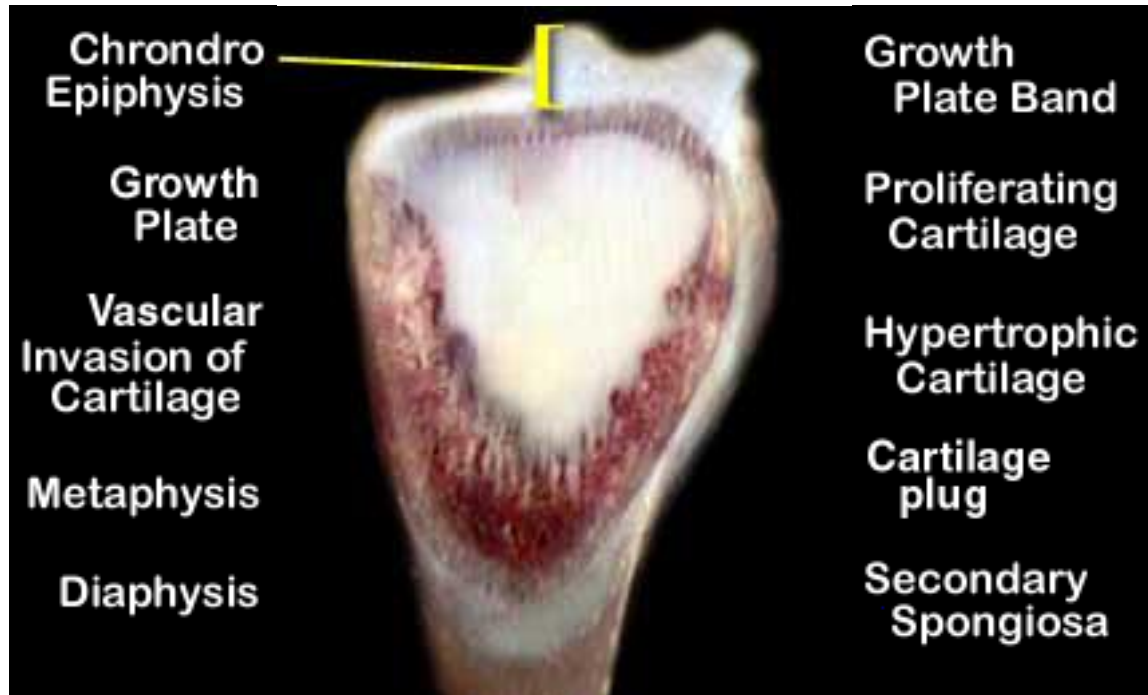



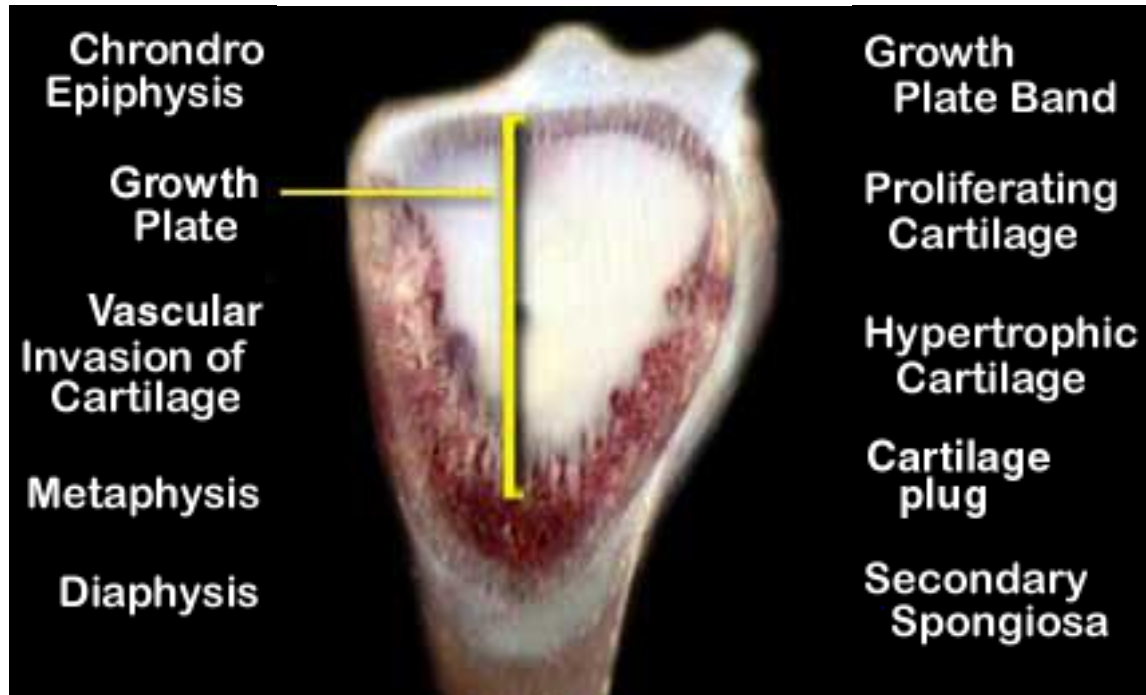
## Tibial Dyschondroplasia (Score 3)



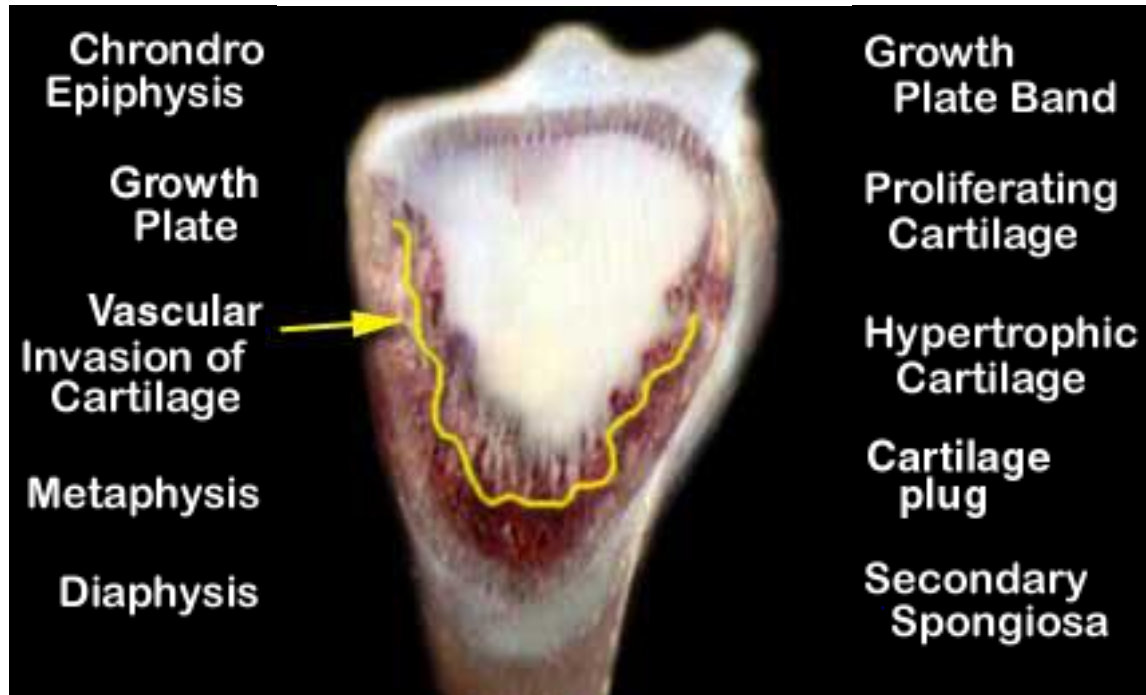## Tibial Dyschondroplasia (Score 3)



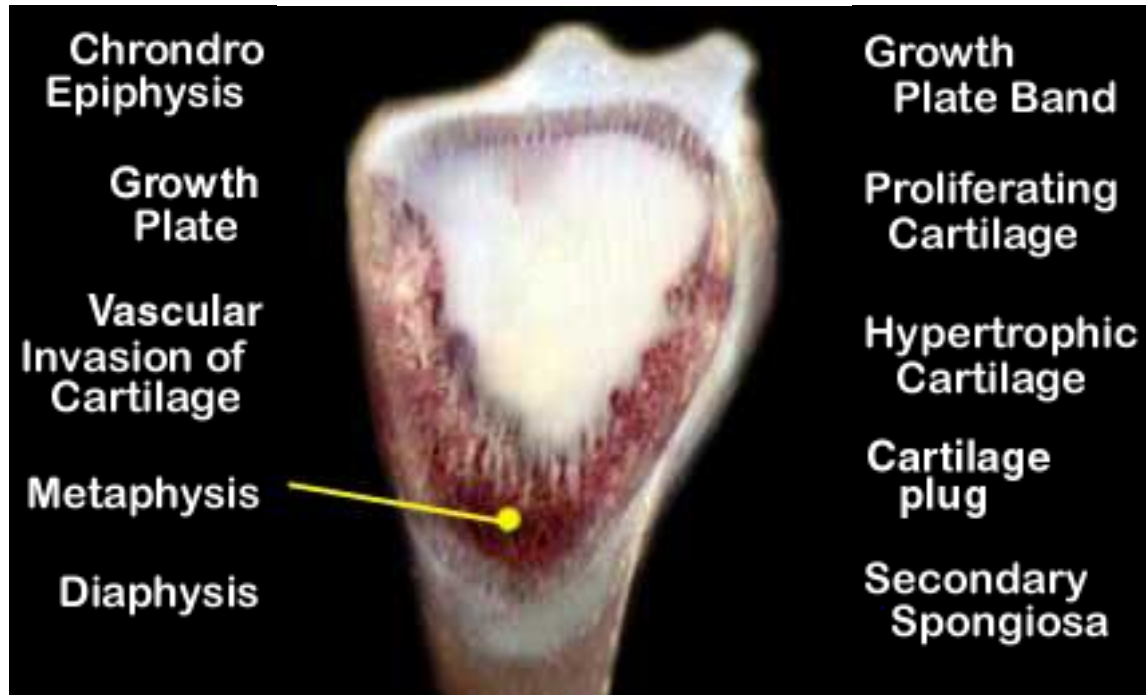
## Tibial Dyschondroplasia (Score 3)



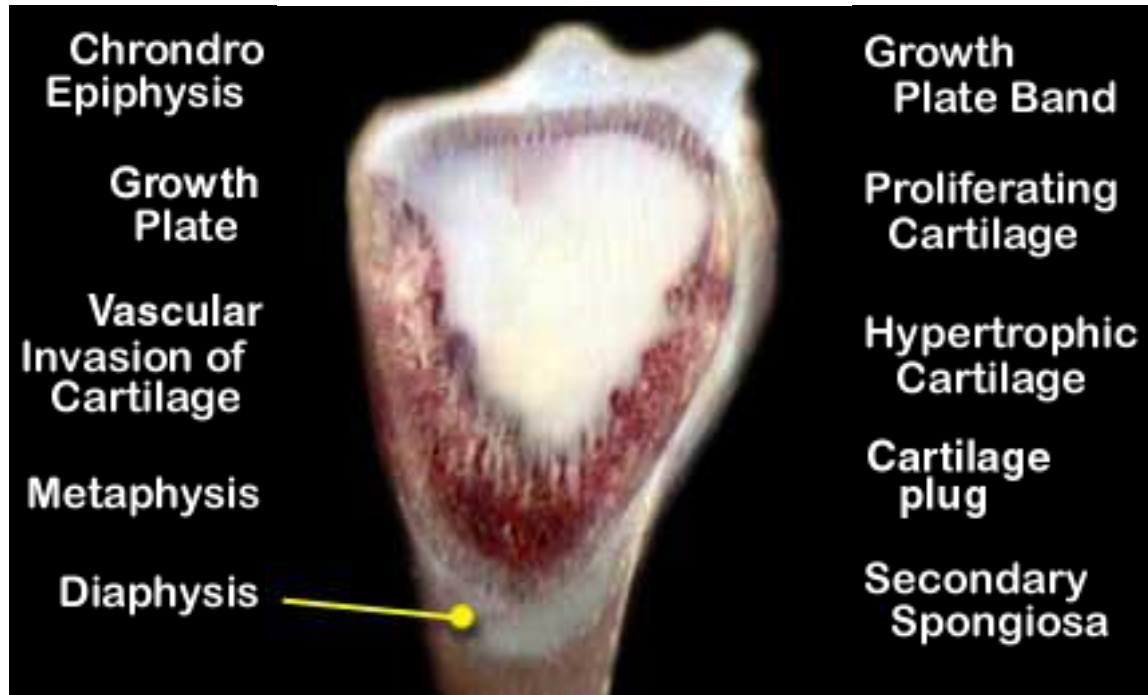
## Tibial Dyschondroplasia (Score 3)



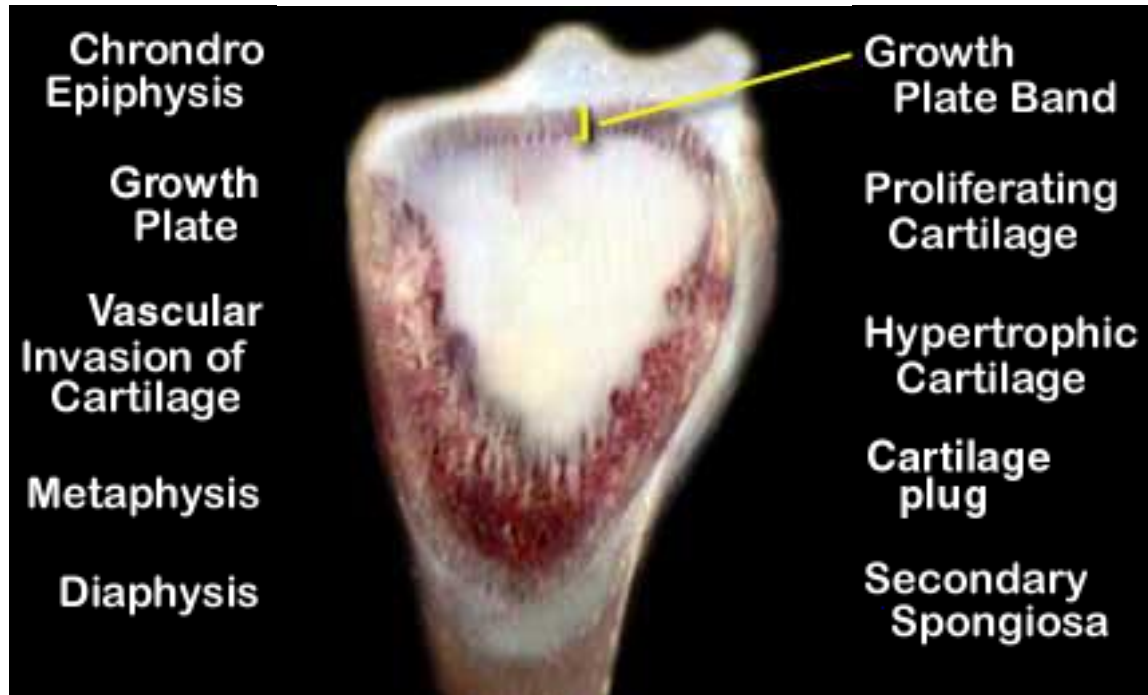## Tibial Dyschondroplasia (Score 3)



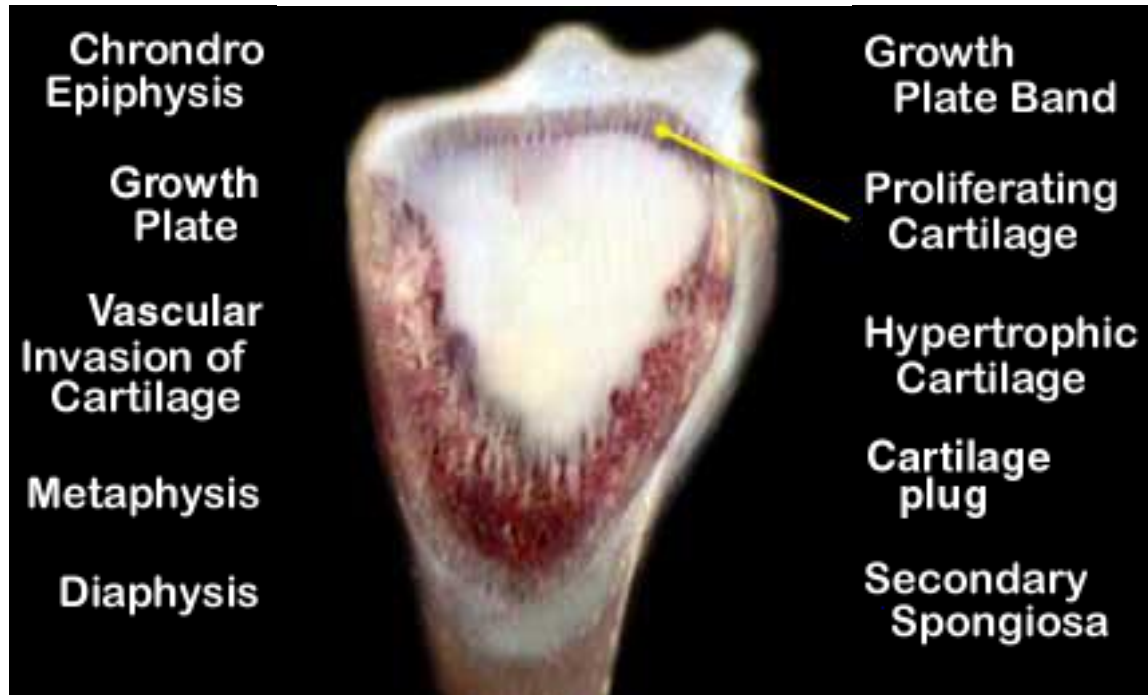## Tibial Dyschondroplasia (Score 3)



## Tibial Dyschondroplasia (Score 3)

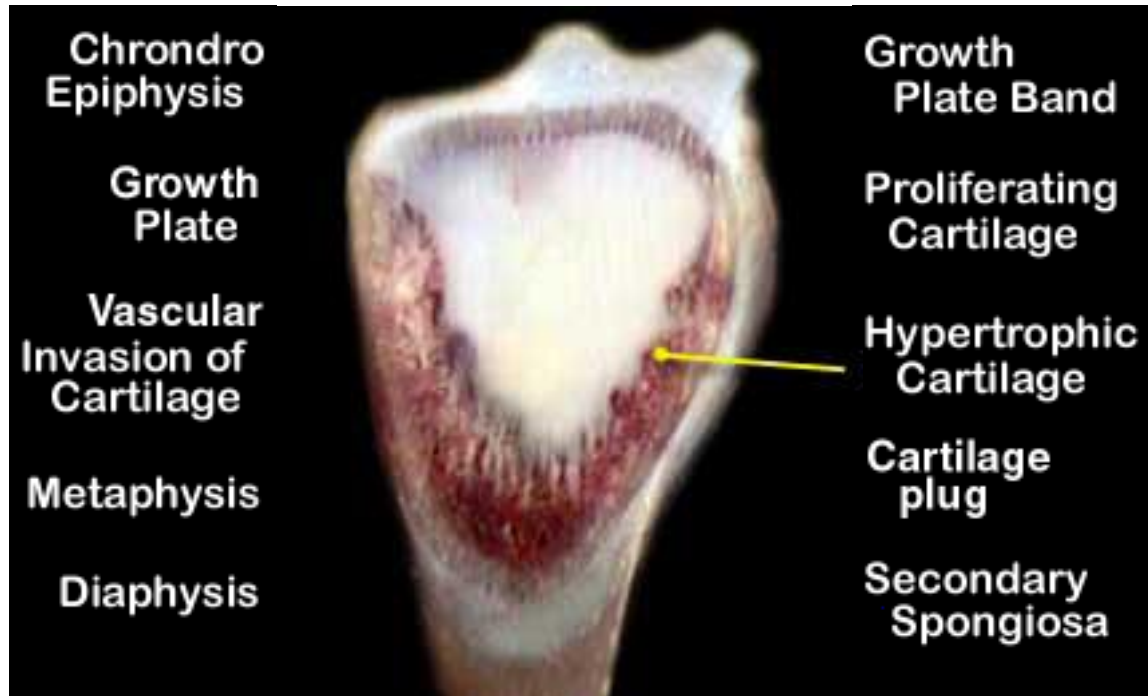


## Tibial Dyschondroplasia (Score 3)

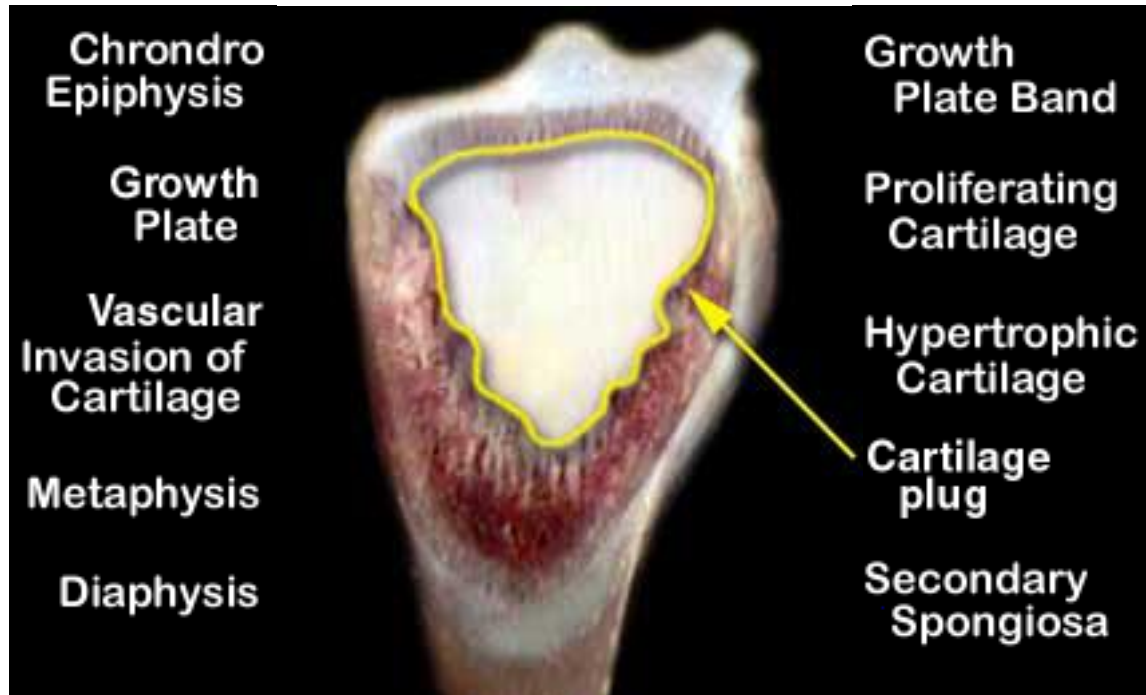




## Tibial Dyschondroplasia (Score 3)



## Tibial Dyschondroplasia (Score 3)



## Tibial Dyschondroplasia (Score 3)

